









Submitted:
29.11.2021
Accepted:
22.02.2022
Published:
13.04.2022

Suspicion of recurrent osteosarcoma in a patient with pseudotumour adjacent to the endoprosthesis

Marek Duczkowski¹ , Agnieszka Duczkowska¹ , Elżbieta Michalak² ,
Agnieszka TomasiK-Kowalska¹ , Sylwia Szkudlińska-Pawlak¹ ,
Bartosz Pachuta³ , Anna Raciborska³ , Monika Bekiesińska-Figatowska¹ 

¹ Department of Diagnostic Imaging, Institute of Mother and Child, Poland

² Department of Pathomorphology, Institute of Mother and Child, Poland

³ Department of Oncology and Surgical Oncology for Children and Youth, Institute of Mother and Child, Poland

Correspondence: Agnieszka Duczkowska, Department of Diagnostic Imaging, Institute of Mother and Child, Kasprzaka 17a, 01-211, Warsaw, Poland;
e-mail: agnieszka.duczowska@gmail.com

DOI: 10.15557/JoU.2022.0023

Keywords

pseudotumor;
endoprosthesis;
osteosarcoma;
recurrence

Abstract

Purpose: Pseudotumor is a rare complication after arthroplasty, most often of the hip joint, in response to metal particles present in the implant. There are merely sporadic reports of pseudotumor in patients with bone sarcoma after sparing surgery with endoprosthesis implant. The aim of this study is to present the characteristic imaging features of pseudotumor. **Case report:** We present a case of a 21-year-old male patient in whom a scheduled follow-up ultrasound revealed a painless lesion suspected of local recurrence at the border of the endoprosthesis and the bone stump 3.5 years after the end of treatment for osteosarcoma of the femur. Histopathology of the biopsy specimen revealed that the lesion was a pseudotumor. **Conclusions:** Although pseudotumor is sporadic in patients treated with endoprosthesis for bone sarcoma, their prolonged survival could bear the risk of such a complication. Imaging studies, in particular ultrasound, may be helpful in differentiating from local recurrence of sarcoma, however, the histopathology of the specimen obtained by open biopsy at a reference center is crucial for the final diagnosis.

Introduction

In recent years, endoprosthesis has significantly evolved as a treatment method in oncological surgery. It has significantly decreased the number of extremity amputations in cancer patients, which is highly important in children⁽¹⁾. The main complications after endoprosthesis implantation include infections and periprosthetic fractures⁽¹⁾. Pseudotumor is a rare, but significant complication, reported primarily in patients after hip joint implantation as an immune response induced by metal particles contained in the implant, most often a cobalt-chromium alloy (Co-Cr)⁽²⁾.

Case report

A 21-year-old male patient presented for scheduled follow-up imaging according to the oncological protocol 3.5 years

after the end of treatment for osteosarcoma in the distal metaphysis of the right femur diagnosed over 4 years earlier (Fig. 1). The patient primarily received a full course of induction chemotherapy, followed by a sparing treatment with endoprosthesis implantation (Fig. 2). Adjuvant chemotherapy was also administered. To date, the patient had no metastases or recurrence of local disease, and he reported no symptoms on the day of the visit. On ultrasound (US) a hypoechoic lesion of 19 × 15 × 5 mm (Fig. 3A) was visualized at the border of the femoral stump and the endoprosthesis, without vascularity in the color Doppler US (Fig. 3B), and was assessed as a fluid reservoir. During the next scheduled 6-month follow-up, ultrasound showed progression of the lesion to 37 × 43 × 15 mm (Fig. 4A), heterogeneous echogenicity, and poor vascularization in the color Doppler (Fig. 4B). The radiograph (X-ray) showed an area of osteolysis in the stump of the femur at the site of the lesion (Fig. 5). There was a clinically palpable hard tumor with a diameter of a few centimeters, attached to

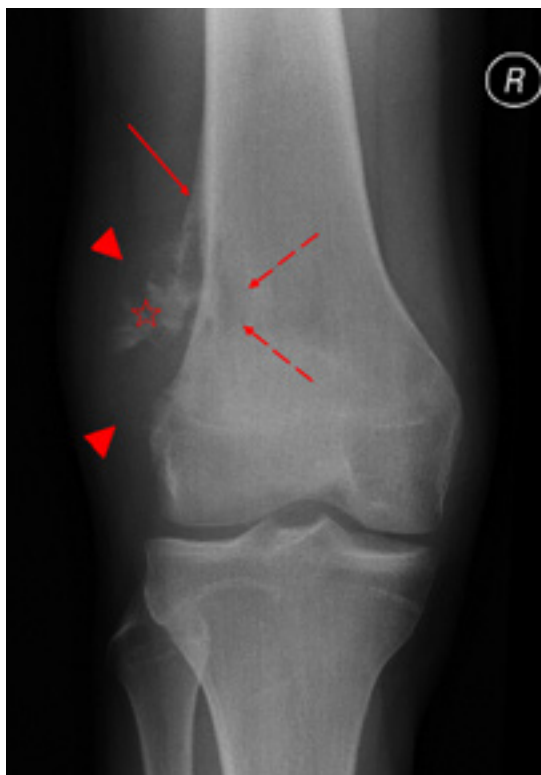

Fig. 1. Anteroposterior radiograph of the right knee joint. Mixed lytic and sclerotic tumor in the distal metaphysis of the femur with radiographic characteristics of malignancy, i.e., detachment of the periosteum in the form of a Codman triangle (continuous arrow), a poorly defined area of osteolysis in the bone (dashed arrows), and the shadow of a periosteal tumor at the lateral side (arrowheads), with visible bone formation (asterisk) – initial examination

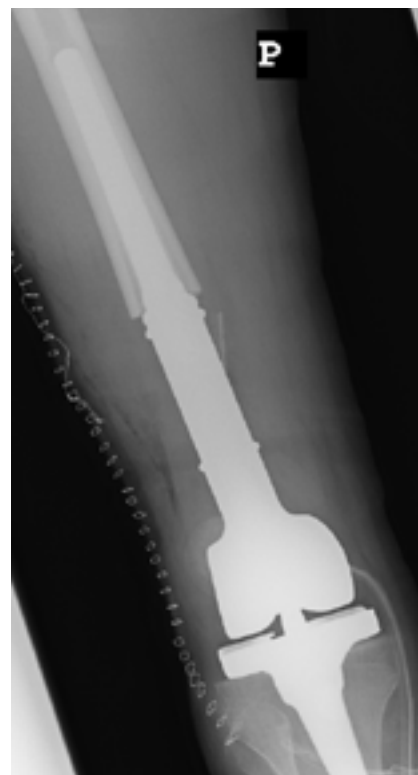

Fig. 2. Anteroposterior radiograph of the right knee joint after tumor resection and implantation of a femoral endoprosthesis with a knee joint – postoperative imaging

the bone, painless on palpation; the skin above the tumor was unchanged. Bone scintigraphy performed a few days before the ultrasound revealed an increased radiotracer uptake at this site. Laboratory tests performed on the same day showed only a mildly elevated C-reactive protein (CRP) at 5.11 mg/L (norm: 0–5), while other parameters remained without significant deviations (e.g., white blood cell count

(WBC) $3.52 \times 10^3/\mu\text{L}$ (norm: 4–10), lactate dehydrogenase (LDH) concentration 167 U/L (norm: 135–225)); control tests performed after 2 weeks showed normal results (CRP 1.27 mg/L, WBC $7.41 \times 10^3/\mu\text{L}$, LDH 152 U/L).

Based on the ultrasound and X-ray findings, a local recurrence was suspected. Extension of diagnostics with computed tomography (CT) and magnetic resonance imaging (MRI) was abandoned due to the lack of expected diagnostic benefits (potential artifacts caused by endoprosthesis). Open tumor biopsy was performed three weeks after

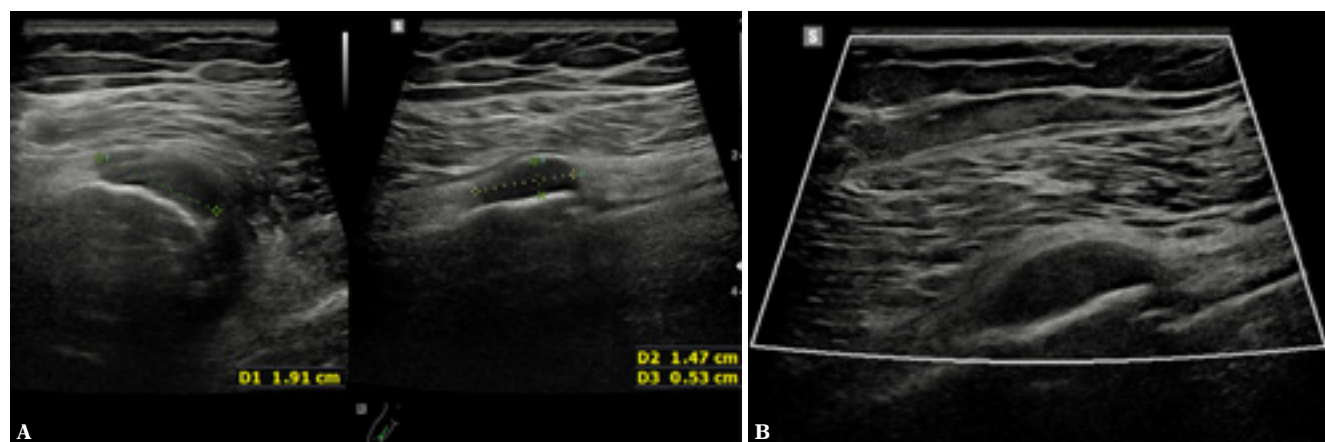


Fig. 3. Ultrasound performed 3.5 years after the completion of oncological treatment. Hypoechoic lesion located at the border of the femoral stump and endoprosthesis (A), nonvascularized in the color Doppler US (B)

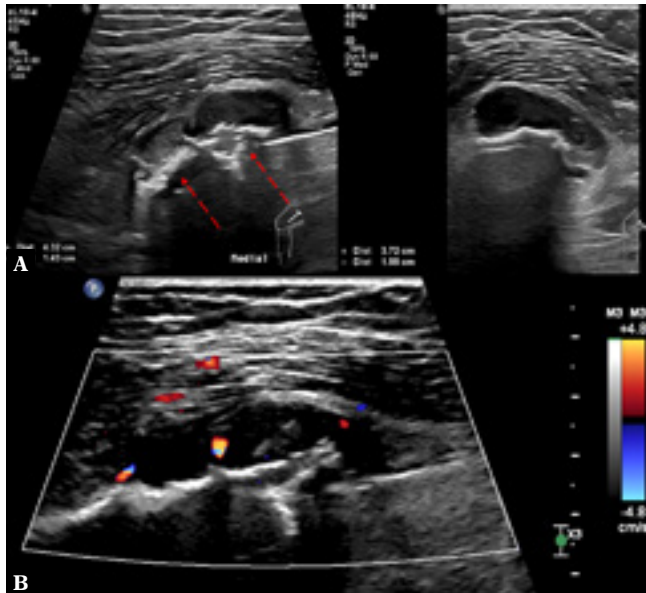


Fig. 4. Ultrasound performed 4 years after the completion of treatment (6 months after the previous examination). Progression of the lesion size and destruction of the cortical bone (dashed arrows) not visible 6 months earlier (**A**); vascularization of the lesion in the color Doppler US (**B**)

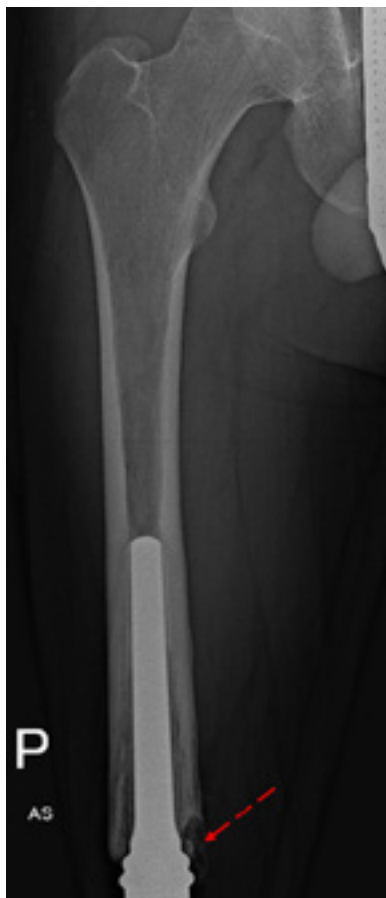

Fig. 5. Anteroposterior radiograph of the right femoral stump performed 4 years after the completion of treatment. The area of osteolysis (dashed arrow) at the medial side of the femoral stump

the second ultrasound. A well-defined, encapsulated soft tissue lesion was visualized intraoperatively. The capsule and the tissue from inside the lesion, as well as a fragment of the femoral stump from the immediate vicinity of the tumor, were collected for histopathology.

Numerous fragments of collagenized connective tissue with clusters of macrophages laden with metal particles, bone fragments with numerous macrophages laden with granular contents, fragments of flaccid, hypocellular cartilage, and strands of mineralized fibrin were described in the histopathological report (Fig. 6). No neoplastic cells were found.

Discussion

Pseudotumor is a complication most often reported in patients following non-oncologic hip arthroplasty, less often knee arthroplasty, and is triggered by metal particles used for production of the implant. The pathogenesis has not been clearly determined but it seems that it is either excessive implant wear (caused by poor quality or incorrect placement), or individual hypersensitivity to a given metal (or metal alloy), or both⁽³⁾. Pseudotumor in patients

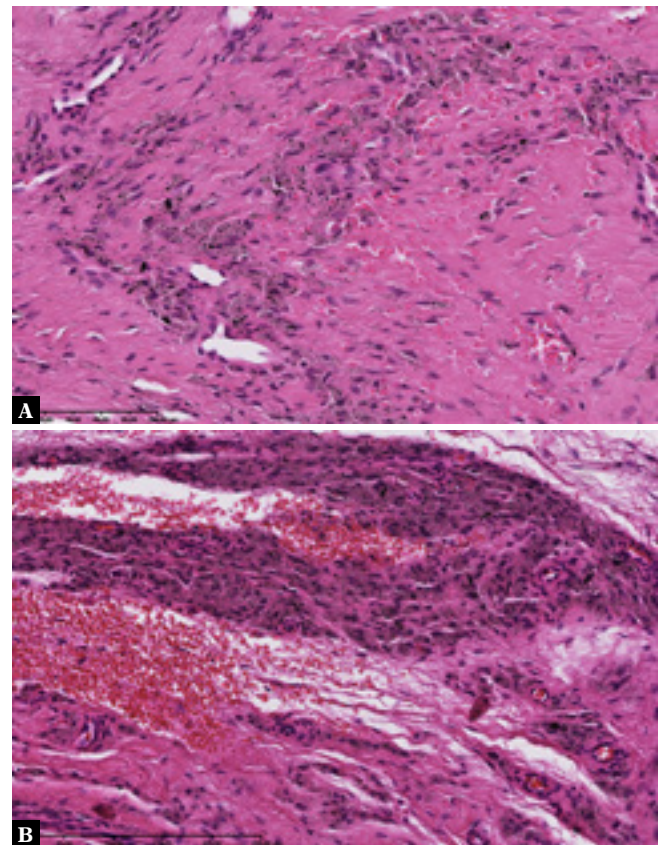


Fig. 6. Histopathological specimens, hematoxylin and eosin staining. Collagenized connective tissue with numerous histiocytes laden with finely granular metal particles (**A**); highly vascularized connective tissue with hemorrhages and clusters of mononuclear and multinuclear histiocytes laden with fine jet black metal particles (**B**)

with hip replacement is most often (57–78% of cases) detected by chance, as it is asymptomatic⁽²⁾. In response to metal particles in periprosthetic soft tissues, there is a local release of, among others, IL-1, IL-6, TNF- α and the osteoclastogenic factors RANK and RANKL. Macrophages also play a major role. Histology will reveal a perivascular lymphocytic infiltrate and clusters of plasma cells and macrophages laden with metal particles of a few nanometers⁽⁴⁾, hence another term for pseudotumor is aseptic lymphocyte-dominated vasculitis-associated lesion (ALVAL). On ultrasound, the lesions may present both as thin-walled cysts or well-defined solid tumors, as well as mixed solid-cystic lesions⁽⁵⁾, which may be accompanied by synovial hyperplasia and joint effusion⁽²⁾. X-ray may show osteolytic lesions in the bone⁽²⁾.

The cause of pseudotumor and its imaging features are similar in patients with an implant placed for non-oncological indications and individuals treated for bone sarcoma. However, management is different. In the first case, pseudotumor usually does not require urgent diagnostics, although its management may involve a revision of the endoprosthesis⁽⁶⁾. Obviously, it must be remembered that these patients may also develop a malignant tumor of soft tissues, e.g. malignant fibrous histiocytoma, which is the most common periprosthetic malignant neoplasm, or less frequently liposarcoma, synovial cell sarcoma, malignant peripheral nerve sheath tumor or non-Hodgkin lymphoma⁽²⁾. In contrast, in patients who have undergone treatment for malignant bone tumors, any new solid lesions must be of concern. This was the case in our patient. The lesion at the border of the bone stump and the endoprosthesis, initially nonvascularized in the color Doppler US (which is typical of a pseudotumor⁽⁴⁾), which had significantly enlarged during 6-month follow-up and caused bone osteolysis, required differentiation from local recurrence of osteosarcoma.

Osteosarcoma is the most common primary malignant bone tumor. It usually occurs in the second decade of life and in people aged ≥ 60 . It is derived from primitive mesenchymal cells capable of producing osteoid⁽⁷⁾. In the past, i.e., 40–50 years ago, the only treatment method was amputation of the affected extremity, whereby about 80% of patients died of metastases, mainly to the lungs⁽⁸⁾.

References

- Smolle MA, Andreou D, Tunn PU, Leithner A: Advances in tumour endoprostheses: a systematic review. *EFORT Open Rev* 2019; 4: 445–459.
- Davis DL, Morrison JJ: Hip arthroplasty pseudotumors: pathogenesis, imaging, and clinical decision making. *J Clin Imaging Sci* 2016; 6: 17.
- Campbell P, Ebramzadeh E, Nelson S, Takamura K, De Smet K, Amstutz HC: Histological features of pseudotumor-like tissues from metal-on-metal hips. *Clin Orthop Relat Res* 2010; 468: 2321–2327.
- Ostlere S: How to image metal-on-metal prostheses and their complications. *AJR Am J Roentgenol* 2011; 197: 558–567.
- Lainiala O, Elo P, Reito A, Pajamäki J, Puolakka T, Eskelinen A: Good sensitivity and specificity of ultrasound for detecting pseudotumors in 83 failed metal-on-metal hip replacements. *Acta Orthop* 2015; 86: 339–344.
- Currently, patients receive chemotherapy before surgery and after complete resection of the primary tumor⁽⁹⁾. This has led to a significant increase in the 5-year survival of patients with localized disease from the initial 16% to approximately 70%. Unfortunately, patients with confirmed metastases at diagnosis and those with recurrence still have a much lower survival rate <30%⁽⁷⁾. Hence the histopathological verification of the lesion in the presented case was essential. It must be noted here that both the authors' own experience and the literature data indicate that pseudotumor is an extremely rare complication after endoprosthesis implantation in patients with bone sarcomas. The PubMed database contains merely one report of a similar case, which concerns a patient after treatment of Ewing sarcoma, i.e., the second most common bone sarcoma in children and adolescents after osteosarcoma⁽¹⁰⁾.

Conclusion

Pseudotumor is a rare complication after endoprosthesis implantation in patients treated for bone sarcoma. Prolonged survival of these patients may be associated with an increased risk of this complication. Diagnostic imaging, in particular ultrasound, may be helpful in differentiating from local recurrence of sarcoma, however, histopathology of the specimen obtained by open surgical biopsy at a reference center is crucial for the final diagnosis.

Conflict of interest

The authors do not report any financial or personal affiliation with other persons or organizations that could adversely affect the content of this publication or claim any right to it.

Author contributions

Original concept of study: MD, AD. Writing of manuscript: MD, AD. Analysis and interpretation of data: MD, AD, EM, AT-K. Final acceptance of manuscript: MD, AD. Collection, recording and/or compilation of data: MD, AD, EM AT-K, SS-P, BP. Critical review of manuscript: MD, AD, AR, MB-F.