

Submitted:
26.04.2022
Accepted:
04.07.2022
Published:
01.10.2022

Common carotid artery hematoma following parathyroid adenoma FNA

Antonios Tsakountakis¹, Anna Detoraki², Alexandros Karatzanis³,
Christos V. Ioannou⁴, Eleni E. Drakonaki⁵

¹ School of Medicine, University of Crete, Heraklion, Crete, Greece

² School of Medicine, European University Cyprus, Nicosia, Cyprus

³ Department of Otorhinolaryngology, School of Medicine, University of Crete, Heraklion, Crete, Greece

⁴ Cardiac & Vascular Surgery, University Hospital of Heraklion, School of Medicine, University of Crete, Heraklion, Crete, Greece

⁵ Department of Anatomy, School of Medicine, University of Crete, Heraklion, Crete, Greece

Corresponding author: Eleni E. Drakonaki, Department of Anatomy, School of Medicine, University of Crete, Voutes Campus, GR-71003, Heraklion Crete, Greece;
e-mail: drakonaki@yahoo.gr

DOI: 10.15557/JoU.2022.0040

Keywords

parathyroid FNA;
carotid hematoma;
FNA complications

Abstract

We present a rare case of a common carotid artery wall hematoma after ultrasound-guided parathyroid fine-needle aspiration. The hematoma was detected within seconds from needle insertion, extending along the common carotid artery wall from the lower neck to the common carotid artery bifurcation, and it was quickly restricted with firm pressure. The patient only reported mild discomfort. A follow-up assessment by a vascular surgeon two hours later showed no signs of ischemic events and complete absorption of the hematoma without further clinical consequences. Physicians performing parathyroid fine-needle aspiration must be aware of this rare complication, which may be easily overlooked. Continuous meticulous sonographic surveillance during the fine needle aspiration procedure is the only way to directly diagnose this complication and apply immediate pressure to restrict it.

Introduction

Solitary benign parathyroid adenomas (PA) account for 80% of the causes of primary hyperparathyroidism⁽¹⁾. Besides the typical location of the superior and inferior PA at the posterolateral surface of the middle/superior thyroid lobe and lower thyroid pole, respectively, ectopic adenomas may be found in various other locations between the thyroid and mediastinum^(1,2). Parathyroid vascular supply is also variable, with arterial supply mainly through the inferior thyroid artery and venous drainage via the thyroid venous plexus and inferior thyroid veins, which may range from two to five, with variant configurations⁽¹⁾.

Ultrasound (US)-guided PA fine-needle aspiration (FNA) is a minimally invasive method to localize PA⁽²⁻⁴⁾. Measurement of parathormone in PA FNA washout fluid increases diagnostic accuracy compared to the US and cytology alone, without a significant increase in the number of needle passes compared to the FNA alone^(2,3).

Although parathyroid adenoma FNA is generally considered safe, minor hematomas following the procedure are reported in up to 5% of cases⁽²⁻⁴⁾. We present a case of an ultrasound (US)-guided parathyroid adenoma FNA causing a large common carotid artery (CCA) intramural hematoma that resolved with immediate pressure with no further implications.

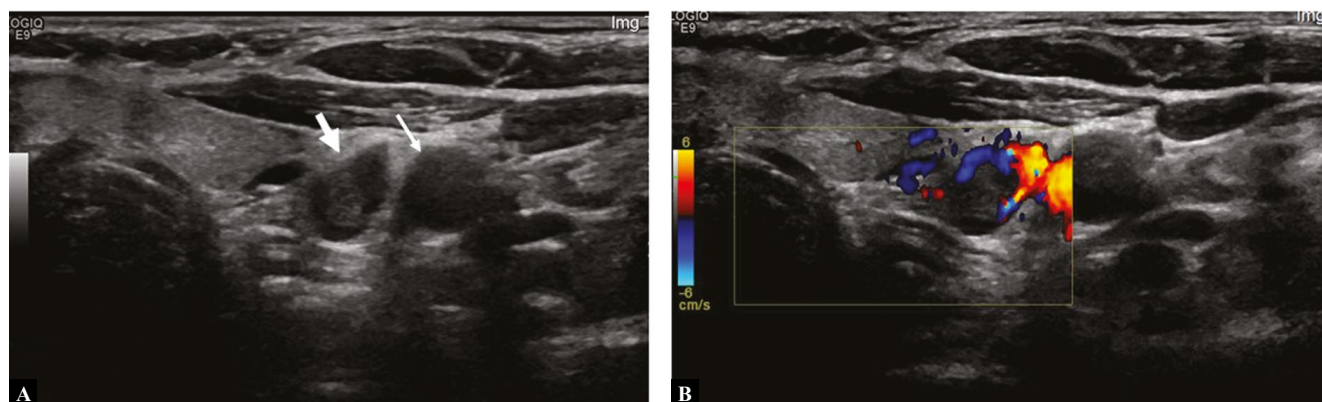


Fig. 1. Axial B-mode (A) and Doppler (B) images of the lower neck showing a parathyroid adenoma (thick arrow) without internal vascularity and a vessel at the periphery of the lesion. Note the left CCA (thin arrow) in the vicinity of the lesion

Case report

A 54-year-old postmenopausal woman came to our department for FNA of a suspected parathyroid adenoma. The patient had a slightly elevated serum PTH (91.3 pg/mL, normal values – N 10.0–88.0 pg/mL), 25-hydroxyvitamin D3 deficiency (21.5 ng/mL, N 30–100 ng/mL), mildly elevated serum calcium (10.16 mg/dL, N 8.2–10.4 mg/dL) and high 24-hour urine calcium (401.28 mg, N 100.0–320.0 mg). The remaining serum markers were normal, there was no other systemic disease apart from osteoporosis (T-score at L1-L4 level of –2.7), and the patient was not under medication. These findings were indicative of a possible parathyroid adenoma. Scintigraphy (99m) Tc-MIBI SPECT/CT scan found no evidence of an adenoma. Neck US revealed an 8.7 × 6.0 × 12 mm ovoid lesion, inferior to the lower pole of the left thyroid lobe, at the paraesophageal space just medially to the left CCA, suspicious of a parathyroid adenoma of the inferior parathyroid glands (Fig. 1A). Doppler US showed peripheral vascularity forming an arch superficial to the lesion (Fig. 1B).

FNA was performed under direct US guidance using the free-hand technique by a radiologist with 12 years of experience using a 27-gauge needle. Aspiration was performed with a mild back-and-forth motion. Within seconds from needle insertion in the lesion, hypoechoic eccentric thickening of the CCA medial wall extending from the lower neck to CCA bifurcation was evident, consistent with a hyperacute hematoma (Fig. 2). The needle was immediately retracted, and firm pressure was applied for about 20 minutes. Intermittent US scanning showed a gradual reduction of the hematoma (Fig. 2C, 2D). The patient reported mild discomfort. A follow-up assessment by a vascular surgeon performed two hours later showed no signs of ischemic events and complete absorption of the hematoma on US.

The lesion was surgically excised uneventfully six months later and the diagnosis of parathyroid adenoma was pathologically confirmed. The surgeon confirmed the presence of an intact vein overlying the lesion, without any signs of hematoma or adhesions.

Discussion

Minor soft tissue hematomas with subsequent spontaneous resolution are common during thyroid FNA (0.3–26%)^(5–7); however, only two cases of intramural CCA hematoma have been reported^(5,6). This may be likely due to the reluctance to report a potentially serious iatrogenic complication. In a study of 7,449 thyroid FNA procedures, a single case of CCA intramural hematoma spreading along the carotid wall for 7 cm in a young patient was reported, resolving with 10 minutes of pressure and antiplatelet treatment⁽⁵⁾. Another case of an intramural CCA hematoma with mild subendothelial spreading has been reported during a free-hand FNA of a complex nodule⁽⁷⁾. Similarly, local pressure was applied, and the hematoma was restricted. It was no longer evident one week later⁽⁷⁾.

In our case, B-mode US showed the presence of acute mildly hypoechoic blood, extending more than 180° of the vessel circumference. There was no Doppler signal inside the thickened wall, thus indicating no signs of CCA dissection or presence of an intimal flap. As acute hemorrhage has similar echogenicity to the echogenic arterial wall, it may not be easy to discriminate between acute intramural hematomas without intimal flap and extramural hematomas. In our case, the semilunar shape, and the extension of the hematoma along the CCA wall selectively rather than into the central neck compartment, strongly suggested an intramural hematoma.

Despite the use of direct US needle visualization, accidental CCA puncture cannot be definitely excluded in our case. During the mild back-and-forth movement of the needle during the procedure, the needle may have accidentally reached the outermost vessel wall layer, inducing injury to the adventitial vasa vasorum externa, and leading to an intramural subadventitial hematoma along the vessel wall. Focal enlargement and widening of the carotid bulb may potentially have contributed to the restriction of the hematoma via mechanical pressure either by the carotid body or the kinking of the vessel. Focal CCA intramural hematomas due to vasa vasorum rupture are very rare, occurring either as a result of trauma or spontaneously, leading to CCA dissection without an intima flap^(8–10). They may pres-

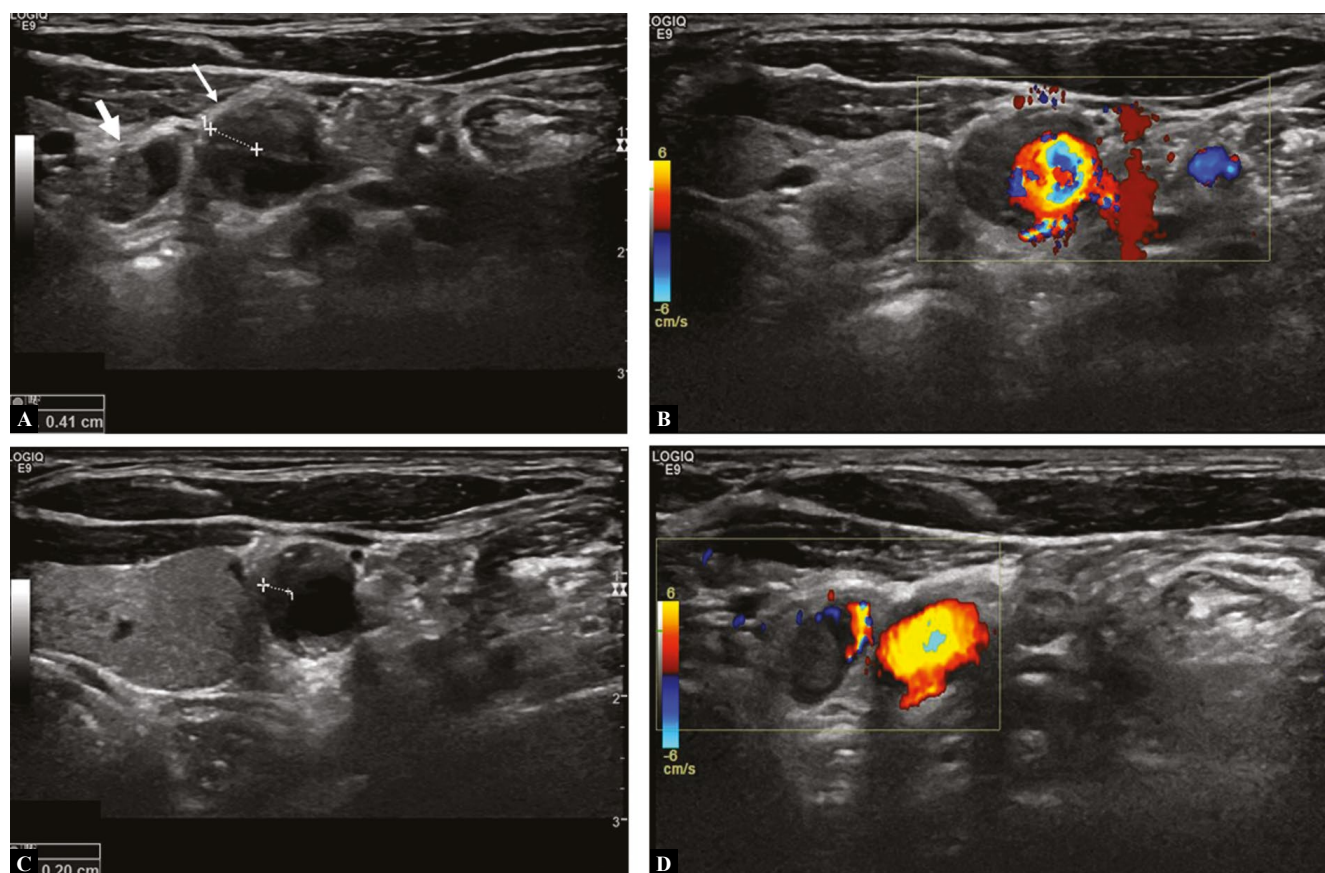


Fig. 2. Axial US image (A) immediately after the FNA. There is a 4 mm thick mildly hypoechoic eccentric thickening of the CCA medial wall (thin arrow) causing restriction to the vessel lumen, consistent with an intramural hematoma (calipers). There is no Doppler signal in the hematoma (B), suggesting the absence of a false lumen. Axial B-mode US image (C) a few minutes later, showing the hematoma (calipers) extending cephalad and measuring 2 mm in thickness. Follow-up axial US image one hour later (D) at the same level as (A), showing complete resolution of the hematoma. The parathyroid adenoma is indicated with a thick arrow

ent with pain or Horner's syndrome, but may occasionally progress to stroke if rupture through the intima occurs⁽⁸⁻¹⁰⁾. In the case report by Anastasilakis *et al.*, the patient mentioned sharp persistent pain probably due to carotid wall puncture⁽⁶⁾. In another patient with minor whiplash injury, a focal CCA intramural hematoma was incidentally found⁽¹⁰⁾. Our patient reported only mild discomfort. This suggests that intramural CCA hematoma may be clinically insidious and thus overlooked. Therefore, physicians performing FNA procedures must rely on the US findings to diagnose this complication and apply immediate pressure. Treatment with antiplatelet agents is controversial in patients without ischemic symptoms^(8,9). In our case, the hematoma was easily restricted with firm pressure alone. US-based and clinical surveillance of the patient is necessary to ensure that the lesion does not progress into the intima layer and lead to ischemic events.

To the best of our knowledge, this is the first case report of a CCA wall hematoma after a parathyroid FNA procedure. Visualization of minor bleeding is expected and depends on the US scanner resolution and the experience of the radiologist to detect it^(2,3). Minor hematomas are reported in up to 5% of parathyroid FNA and are not associated with

any problems during surgical excision of the lesion^(2,3). Signs of hemorrhage have also been found in 4–14% of cases during surgery for parathyroid adenomas⁽³⁾. Intralesional and perilesional hemorrhage induces histologically confirmed fibrotic reaction, leading to adhesions and increased surgical time and difficulty^(2,3). In our patient, though, no macroscopic or microscopic fibrosis was evident, the surgical procedure was standard and uneventful, and there was no mention of intralesional fibrosis in the pathology report. This may be associated with the fact that thin 27-gauge needles were used, and the operator was highly experienced.

Although parathyroid adenomas typically exhibit peripheral arterial vascularity, the presence of an intact vein at the periphery of the lesion was found by the surgeon. This may potentially be attributed to an atypical draining vein, as there is considerable anatomical variation in the venous drainage of the PA to the inferior thyroid vein⁽¹⁾.

In conclusion, this is the first report of a parathyroid US-guided FNA complicated by an intramural hematoma. Physicians performing parathyroid FNA procedures must be aware of this rare complication, which may be easily

overlooked. Continuous meticulous sonographic surveillance during the FNA procedure is the only way to directly diagnose this complication and apply immediate pressure to restrict it.

Conflict of interest

The authors do not report any financial or personal connections with other persons or organizations which might negatively affect the contents of this publication and/or claim authorship rights to this publication.

References

1. Taslakian B, Trerotola SO, Sacks B, Oklu R, Deipolyi A: The essentials of parathyroid hormone venous sampling. *Cardiovasc Intervent Radiol* 2017; 40: 9–21.
2. Obolończyk Ł, Karwacka I, Wiśniewski P, Sworczak K, Oseka T: The current role of parathyroid fine-needle biopsy (P-FNAB) with iPTH-washout concentration (iPTH-WC) in primary hyperparathyroidism: a single center experience and literature review. *Biomedicines* 2022; 10: 123.
3. Bancos I, Grant CS, Nadeem S, Stan MN, Reading CC, Sebo TJ *et al.*: Risks and benefits of parathyroid fine-needle aspiration with parathyroid hormone washout. *Endocr Pract* 2012; 18: 441449.
4. Suzuki A, Hirokawa M, Kanematsu R, Tanaka A, Yamao N, Higuchi M *et al.*: Fine-needle aspiration of parathyroid adenomas: indications as a diagnostic approach. *Diagn Cytopathol* 2021; 49: 70–76.
5. Cappelli C, Pirola I, Agosti B, Tironi A, Gandossi E, Incardona P *et al.*: Complications after fine-needle aspiration cytology: a retrospective study of 7449 consecutive thyroid nodules. *Br J Oral Maxillofac Surg* 2017; 55: 266–269.
6. Anastasilakis AD, Polyzos SA, Nikolopoulos P: Subendothelial carotid hematoma after fine-needle aspiration biopsy of a solitary thyroid nodule. *J Ultrasound Med* 2008; 27: 1517–1520.
7. Polyzos SA, Anastasilakis AD: Systematic review of cases reporting blood extravasation-related complications after thyroid fine-needle biopsy. *J Otolaryngol Head Neck Surg* 2010; 39: 532–541.
8. Lim S, Khanafer A, Misselhorn D, Laing A: Focal common carotid artery intramural haematoma. *N Z Med J* 2012; 126: 82–85.
9. Umana E, Bajwa R, Davidson I, Gallagher D: Hit by the wave: a case of painful Horner's and intramural haematoma of the carotid. *BMJ Case Rep* 2018: bcr2018225660.
10. Viacoz A, Perren F: Focal common carotid artery intramural hematoma. *J Neuroimaging* 2013; 23: 311–313.

Author contributions

Original concept of study: ED; Writing of manuscript: AT, AD, ED; Analysis and interpretation of data: AT, AD, AK, CI, ED; Final approval of manuscript: AT, AD, AK, CI, ED; Collection, recording and/or compilation of data: AK, CI, ED; Critical review of manuscript: AK, CI, ED.