

Submitted:
20.11.2021
Accepted:
16.12.2021
Published:
08.02.2022

Role of lung ultrasound in diagnosing and differentiating transient tachypnea of the newborn and respiratory distress syndrome in preterm neonates

Srinivasan S, Neeti Aggarwal, Sushma Makhaik, Anupam Jhobta, Sumala Kapila, Rohit Bhoil

Department of Radiology, Indira Gandhi Medical College (IGMC), Shimla, Himachal Pradesh, India

Correspondence: Srinivasan S, Department of Radiology, Indira Gandhi Medical College (IGMC), Shimla, Himachal Pradesh, India, Lakkar Bazaar, 171001, Shimla, India; e-mail: srinivasan1985@hotmail.com

DOI: 10.15557/JoU.2022.0001

Keywords

respiratory distress syndrome (RDS); transient tachypnea of the newborn (TTN); lung ultrasonography (LUS); neonatal intensive care unit (NICU)

Abstract

Aim: To evaluate the accuracy of lung ultrasound in diagnosing and differentiating transient tachypnea of the newborn and respiratory distress syndrome in preterm neonates. **Material and methods:** This was a single-center study. From January 2020 to June 2021. A total of 100 preterm neonates, admitted to the neonatal intensive care unit with symptoms of respiratory distress within six hours of birth, including 50 diagnosed with transient tachypnea of the newborn and 50 with respiratory distress syndrome on the basis of clinical examination, laboratory testing, chest X-rays, were recruited in the study. Lung ultrasound was performed in each neonate by a senior radiologist who was blinded to the clinical diagnosis. Lung ultrasound findings in both conditions were analyzed and compared. **Results:** Pulmonary edema manifesting as alveolar-interstitial syndrome, double lung point sign and less commonly as white out lungs in the absence of consolidation has 100% sensitivity and specificity in diagnosing transient tachypnea of the newborn. A combination of three signs of consolidation with air or fluid bronchograms, white out lungs and absent spared areas has 100% sensitivity and specificity for diagnosing respiratory distress syndrome. Double lung point sign was seen only in infants suffering from transient tachypnea of the newborn and consolidation with air or fluid bronchograms only in cases of respiratory distress syndrome. **Conclusion:** Lung ultrasound can accurately diagnose and reliably differentiate transient tachypnea of the newborn and respiratory distress syndrome in preterm neonates. It has advantages that cannot be replicated by chest radiography. Lung ultrasound may be used as an initial screening tool.

Introduction

Transient tachypnea of the newborn (TTN), also referred to as “wet lung”, is one of the most common causes of neonatal dyspnea. It is a benign disorder caused by delayed clearance of lung fluid. Even severe cases respond well to continuous positive airway pressure (CPAP), and most improve rapidly within 24 hours^(1,2).

Respiratory distress syndrome (RDS), arises at or shortly after birth (<24 hours) and its severity increases in the first 48 hours. It is a manifestation of surfactant deficiency. RDS and its associated complications are the most common causes of neonatal morbidity^(3,4).

Both conditions are common in preterm infants. The incidence of TTN in preterm neonates is 10%⁽¹⁾, and approximately four out of five cases of RDS occur in the prematurely born (<37 weeks)^(5,6). Patients with TTN also present with respiratory distress in early stages, hence it is difficult to distinguish it from RDS⁽⁷⁾. Moreover, chest X-ray (CXR) has poor sensitivity and specificity to detect pulmonary edema, which is the main pathological manifestation of TTN. This is due to the ability of X-rays to detect increased alveolar aeration, while failing to demonstrate the interstitial involvement that ultrasound does⁽⁸⁾. According to the literature, the agreement between clinicians and radiologists is only 48% when diagnosing TTN, while it is 95% when diagnosing RDS⁽⁹⁾.

CXR has considerable intra and inter observer variability, and exposes patients to the risk of ionizing radiation⁽¹⁰⁾. Neonates, due to their small size, closer proximity of radiosensitive organs, and the presence of rapidly dividing cells, which cannot repair mutated DNA, are more susceptible to the damaging effects of radiation, approximately 6–9 times more than in 60-year-olds. With neonates undergoing multiple CXR examinations during their stay in the NICU, efforts have been made to identify a safer alternative diagnostic test^(11,12).

Hence the need for an alternative diagnostic tool to diagnose and differentiate TTN and RDS. In recent times, lung ultrasound (LUS) is emerging as a promising tool to diagnose respiratory diseases in neonates. It is accurate, non-ionizing, easy to operate, and can be performed at bedside, especially in emergency intensive settings.

Methods

This was a single-center study. From January 2020 to June 2021, a total 100 preterm neonates admitted to the neonatal intensive care unit (NICU) with symptoms of respiratory distress within six hours of birth, including 50 diagnosed with TTN and 50 with RDS on basis of clinical examination, laboratory testing, and chest X-ray (AP and lateral views), were recruited in the study. LUS was performed in each neonate by a senior radiologist who was blinded to the clinical diagnosis. The LUS findings in RDS and TTN were analyzed and compared.

Ethical statement and approval

Prior approval for pursuing this study was obtained from an institutional ethical committee. A written informed consent was sought from each participant's parent after explaining the purpose of study.

Equipment

Sonograms were obtained by using a real-time Mindray – USG machine and 7.5MHz linear transducer.

Technique

The enrolled patients were scanned in six anatomic lung zones by transthoracic approach: bilateral anterior (parasternal line to anterior axillary line), lateral (anterior axillary line to posterior axillary line), and posterior (posterior axillary line to paravertebral line) lung zones in sagittal planes, with patients in the supine or lateral recumbent position. The ultrasound findings were recorded in the hard drive as images.

Ultrasound indices used in this study

- A-lines (Fig. 1) are reverberation artifacts arising from the pleural line and are seen as a series of parallel and equidistant lines beyond the pleural line⁽¹³⁾.

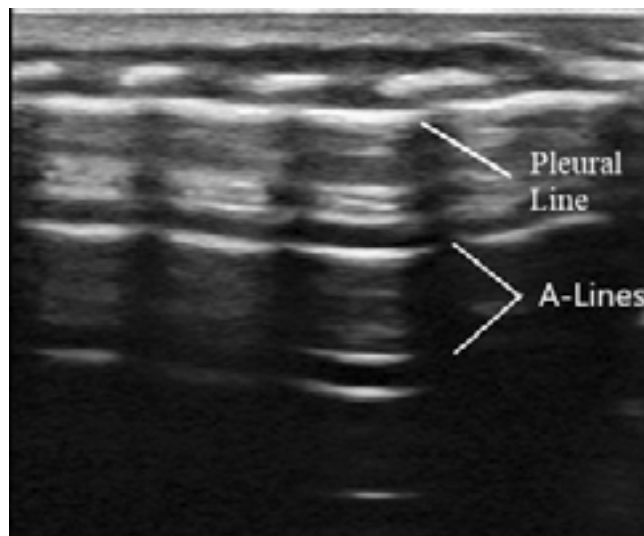


Fig. 1. USG appearance of normal lung – which appears hypoechoic with visible pleural and A-lines. Curvilinear echogenic ribs are also seen, casting posterior acoustic shadowing

- B-lines project from the pleural line to the edge of the screen and move synchronously with respiration. The presence of B-lines is caused by the alveolar gas–liquid interface. They are ring down artifacts^(14–16).
- White out lungs: defined as the presence of compact B-lines in six areas without horizontal reverberation⁽¹⁶⁾. They appear as 3-mm apart confluent lines and represent alveolar edema⁽¹⁰⁾.
- The alveolar-interstitial syndrome is the presence of more than three B-lines in every examined area or the presence of white lung areas. They are visible as echogenic ring down artifacts that are 7 mm apart arising from the pleural line and are representative of edema involving interlobular septa⁽¹⁷⁾.
- Lung consolidation: defined as areas of hepatization (tissue pattern) with the presence of air or fluid bronchograms^(4,17).
- Pleural effusion: defined as anechoic-dependent collections limited by the diaphragm and the pleura⁽¹⁰⁾.
- Double lung point (DLP) sign: arises due to a difference in the severity or nature of pathology in different areas of the lung. A clear difference is observable in the longitudinal scan between the upper lung fields, with fewer compact B-lines and lower lung fields with more compact lung fields; this sharp cut-off point between the upper and lower lung fields is known as the double lung point⁽¹⁴⁾.

Results

The mean gestational age in RDS patients was 31.32 ± 2.4 weeks and 33.00 ± 1.6 weeks in TTN patients. The mean birth weight was $1,511 \pm 049$ grams in the RDS group, and $2,030 \pm 510$ grams in the TTN group. In our study, we found that the gestational age and birth weight were lower in preterm infants with RDS than in infants with TTN. This was in accordance with the findings of the study performed by Liu S *et al.* in 2005⁽¹⁸⁾.

Tab. 1. General information about patients in the two groups

Neonate group	GA (weeks)	Birth weight (GMS)	Gender (M/F)	CS (n)
RDS (n = 50)	31.3 ± 2.4	1511 ± 049	28/22	32
TTN (n = 50)	33.0 ± 1.6	2030 ± 510	31/19	33

GA – gestational age; CS – caesarean section; M – males; F – females; n – number

Sex distribution in the RDS group was males 52% and females 48%, and in the TTN group it was males 66% and females 34%. These findings were in accord with the studies conducted by Mlay and Maitji who found that RDS was more common in males than females⁽¹⁹⁾, and by Costa *et al.* who showed that TTN was more prevalent in males than females⁽²⁰⁾.

The number of caesarean sections in the RDS group was 32 (64%), and in the TTN group it was 33 (66%) (Tab. 1). In our study, the incidence of TTN and RDS was higher in newborns delivered by caesarean section. This was in accordance with the studies done by Levine *et al.* who found that newborns delivered by caesarean section have an increased incidence of respiratory disorders compared to those delivered vaginally⁽²¹⁾, and in agreement with the study done by Chandrasekhar, who found TTN to be significantly increased among caesarean deliveries⁽²²⁾.

The Downes score in the RDS group was <4 in 2 (4%), and 4–7 in 37 (96%) neonates. The Downes score in the TTN group was <4 in 28 (56%), and 4–7 in 22 (44%) subjects. A score of >7 was not seen in any of the groups. The Downes score has good correlation with physiological parameters such as arterial pH and blood-gas as well as mortality.

Ultrasound findings in RDS

The findings are summarized in Tab. 2. The most consistent finding in the RDS group was lung consolidation with air or fluid bronchograms. It was seen in every (100%) neonate with RDS and has 100% sensitivity, specificity, and positive predictive value in diagnosing RDS. In most cases, consolidations were seen in the sub-pleural location (Fig. 2), and only in a few cases a larger area of consolidations was seen. Absent A-lines and white out lungs (Fig. 3) were seen in 44 (88%) of RDS infants and has 88% sensitivity and 94% specificity in

Tab. 2. USG findings in the RDS group

LUS findings in RDS	Observations			
	Sensitivity	Specificity	PPV	NPV
Consolidation with air or fluid bronchograms	100%	100%	100%	100%
White out lungs (severe alveolar-interstitial syndrome)/Absent A-lines	88.0%	94.0%	93.6%	88.7%
Absence of spared areas	100%	94.0%	94.3%	100%
Pleural line abnormalities	100%	0%	50%	-
Pleural effusion	18.0%	90.0%	64.2%	52.3%

PPV – positive predictive value; NPV – negative predictive value

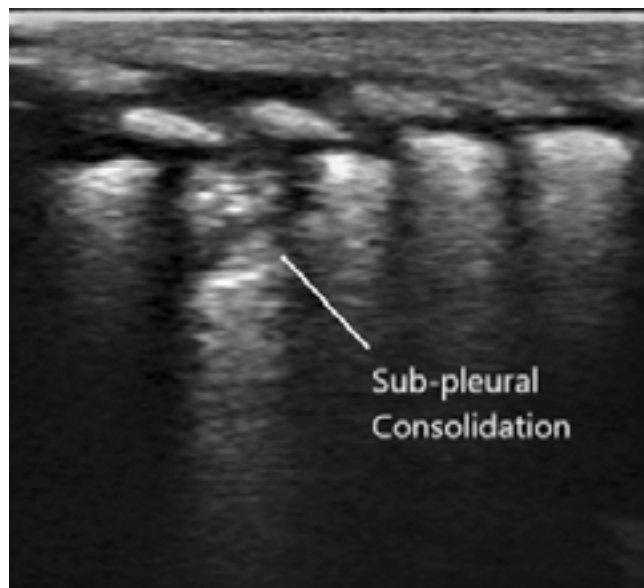


Fig. 2. Area of subpleural consolidation with air bronchograms

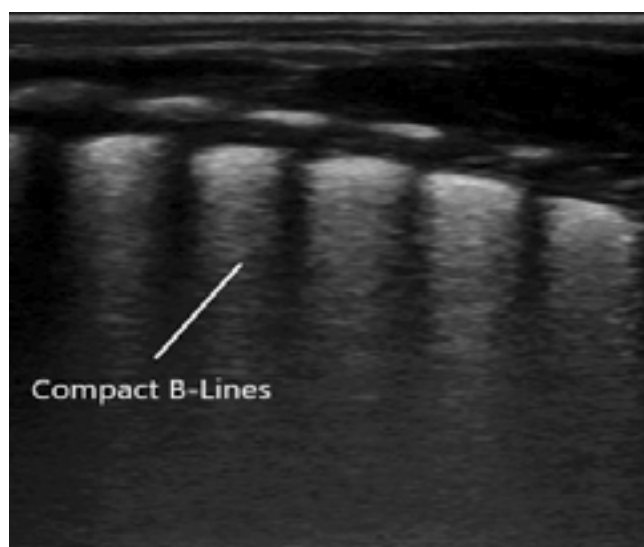


Fig. 3. White out lung arising from 3-mm apart confluent B-lines and represents alveolar edema

diagnosing RDS. There were no spared areas, with findings seen consistently in both lung fields. The absence of a spared area has 100% sensitivity and 94% specificity in diagnosing RDS. Pleural line abnormality in form of thickening or irregularity was seen in all (100%) cases of RDS. However, double lung point sign was not seen in any RDS patients.

Ultrasound findings in TTN

The findings are summarized in Tab. 3.

The most consistent feature in the TTN group was pulmonary edema manifesting as alveolar-interstitial syndrome (Fig. 4), double lung point sign (Fig. 5) and less commonly as lung white out lungs. Alveolar-interstitial syndrome and

Tab. 3. USG findings in the TTN group

LUS findings in TTN	Observations			
	Sensitivity	Specificity	PPV	NPV
Double lung point (DLP) sign	94.00%	100%	100%	94.3%
Alveolar-interstitial syndrome	94.0%	88.0%	88.7%	93.6%
Pleural line abnormalities	100%	0%	50%	-
Absent A-lines/ White out lungs	6.00%	0%	5.7%	0%
Pleural effusion	10.0%	82.0%	35.7%	47.7%

PPV – positive predictive value; NPV – negative predictive value

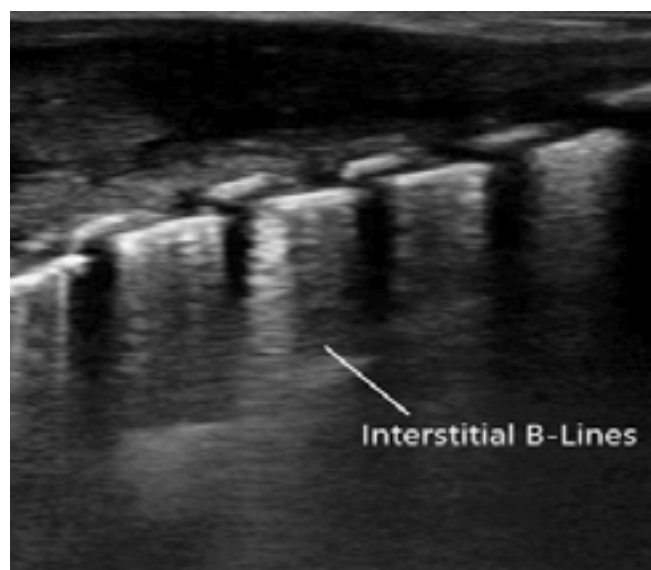


Fig. 4. Alveolar-interstitial syndrome, characterized by abnormal B-lines which are echogenic ring down artifacts, and are 7 mm apart arising from the pleural line and are representative of edema involving interlobular septa

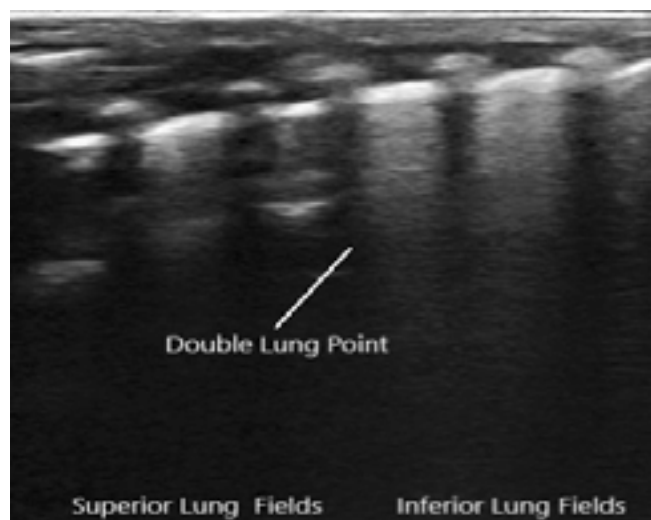


Fig. 5. Double lung point sign, a sharp cutoff point arising due to more compact B-lines in lower and less compact B-lines in upper lung fields

DLP were both observed in 47 (94%) patients. The presence of DLP has a sensitivity of 94%, specificity and positive predictive value of 100% in diagnosing TTN. The presence of alveolar-interstitial syndrome has 94% sensitivity and 88% specificity in diagnosing TTN. In severe cases, white out lungs with complete A-line disappearance without DLP were seen, and observed in only 3 (6%) TTN patients.

Pleural line abnormalities were found in all the cases (100%) of TTN. The ultrasound features were inconsistent both between the two lung fields and within different zones in a single lung field. However, no lung consolidation was found in any of the patients.

Discussion

TTN and RDS are the most common causes of neonatal dyspnea and are more prevalent in preterm infants.

DLP was seen only in infants suffering from TTN, and was not observed in any RDS cases. In the course of TTN, the mechanism of fluid clearance, which in the newborn period takes place largely through capillaries, is impaired. Since lung mass is predominant in the lower pulmonary fields with respect to the apices, alveolar and interstitial fluid is also represented there. It is possible that in those areas increased capillary recruitment occurs in order to remove the excess liquid, which generates imbibition of the interlobular septa. The presence of compact B-lines is the result of a greater amount of water in the lower lung fields, while the less compact B-lines present in the upper areas are related to a milder interstitial syndrome leading to the formation of DLP⁽²³⁾. Its presence has 94% sensitivity, and 100% specificity and positive predictive value in diagnosing TTN, while its presence rules out RDS. Previous research results have indicated that the sensitivity of DLP for the diagnosis of TTN is 100%⁽¹⁶⁾. In our study, three cases of severe TTN demonstrated white out lungs, hence DLP was not seen, resulting in disagreement. However, neither was consolidation seen in these cases. The presence of consolidation has 100% negative predictive value for TTN.

Thus, the presence of pulmonary edema manifesting as alveolar-interstitial syndrome, double lung point sign and less commonly as white out lungs in the absence of consolidation has 100% sensitivity and specificity in diagnosing TTN.

Consolidation with air or fluid bronchograms was seen only in infants suffering from RDS and was not observed in any TTN cases. Its presence has 100% sensitivity, specificity, and positive predictive value in diagnosing RDS. Consolidations were asymmetrically distributed and seen more often in posterior zones. This could have resulted from the continuous supine position of neonates in NICU.

White out lungs, which implies severe alveolar-interstitial syndrome, associated with complete A-line disappearance, was seen in 88% of RDS infants and only in 6% of TTN patients. The absence of spared areas was seen in 100% of RDS and only 6% of TTN infants. This 6% of TTN patients

Tab. 4. Distribution of ultrasound findings in the two groups

Ultrasound findings	RDS group (n = 50)	TTN group (n = 50)	p value
Consolidation with air or fluid bronchograms	50 (100%)	0	<0.001*
Double lung point sign	0 (0%)	43 (86%)	<0.001*
White out lungs (severe alveolar-interstitial syndrome)/Absent A-lines	44 (88%)	3 (6%)	<0.001*
Interstitial syndrome	06 (12%)	47 (94%)	<0.001*
Absence of spared areas	50 (100%)	3(6%)	<0.001*
Pleural effusion – unilateral/ bilateral	09 (18%)	05 (10%)	>0.05**
Pleural line abnormalities	50 (100%)	50 (100%)	>0.05**

* Not significant at p value <0.05
** Significant at p value <0.001

had white out lungs, which is the severe manifestation of pulmonary edema.

Thus, a combination of three signs of consolidation with air or fluid bronchograms, white out lungs and absent spared areas has 100% sensitivity and specificity for diagnosing RDS.

References

- Greenough A: Transient tachypnea of the newborn. In: Greenough A, Milner AD (eds.): Neonatal Respiratory Disorder, 2nd ed. London: CRC Press. 2003: 272–277.
- Yurdakök M: Transient tachypnea of the newborn: what is new? J Matern Fetal Neonatal Med 2010; 23 Suppl 3: 24–26.
- Morris SJ: Radiology of the chest in neonates. Curr Paediatr 2003; 13: 460–468.
- Lovrenski J: Lung ultrasonography of pulmonary complications in preterm infants with respiratory distress syndrome. Ups J Med Sci 2012; 117: 10–17.
- Mactier H, Bates SE, Johnston T, Lee-Davey C, Marlow N, Mulley K *et al.*: Perinatal management of extreme preterm birth before 27 weeks of gestation: a framework for practice. Arch Dis Child Fetal Neonatal Ed 2020; 105: 232–239.
- Wang J, Liu X, Zhu T, Yan C: Analysis of neonatal respiratory distress syndrome among different gestational segments. Int J Clin Exp Med 2015; 8: 16273–16279.
- Rocha G, Rodrigues M, Guimarães H: Respiratory distress syndrome of the preterm neonate – placenta and necropsy as witnesses. J Matern Fetal Neonatal Med 2011; 24: 148–151.
- Staub NC: Pulmonary edema. Physiol Rev 1974; 54: 678–811.
- Kurl S, Heinonen KM, Kiekara O: The first chest radiograph in neonates exhibiting respiratory distress at birth. Clin Pediatr (Phila) 1997; 36: 285–289.
- Copetti R, Cattarossi L, Macagno F, Violino M, Furlan R: Lung ultrasound in respiratory distress syndrome: a useful tool for early diagnosis. Neonatology 2008; 94: 52–59.
- Hall EJ, Brenner DJ: Cancer risks from diagnostic radiology: the impact of new epidemiological data. Br J Radiol 2012; 85: e1316–1317.
- Raimondi F, Migliar F, Sodano A, Valone G, Ferrara T, Maddaluno S *et al.*: Point-of care chest ultrasound in the Neonatal Intensive Care Unit. J Pediatr Neonatal Individual Med 2013; 2: e020214.
- Lichtenstein D, Mézière G, Biderman P, Gepner A, Barré O: The comet-tail artifact. An ultrasound sign of alveolar-interstitial syndrome. Am J Respir Crit Care Med 1997; 156: 1640–1646.
- Lichtenstein D, Mezière G: A lung ultrasound sign allowing bedside distinction between pulmonary edema and COPD: the comet-tail artifact. Intensive Care Med 1998; 24: 1331–1334.
- Koenig SJ, Narasimhan M, Mayo PH: Thoracic ultrasonography for the pulmonary specialist. Chest 2011; 140: 1332–1341.
- Lichtenstein DA, Lascols N, Mezière G, Gepner A: Ultrasound diagnosis of alveolar consolidation in the critically ill. Intensive Care Med 2004; 30: 276–281.
- Lichtenstein DA: Lung ultrasound in the critically ill. Clinical Intensive Care 2005; 16: 79–87.
- Liu S, Tong X: [The clinical comparative study of preterm respiratory distress syndrome and transient tachypnea of newborn]. Zhonghua Er Ke Za Zhi 2015; 53: 104–108. In Chinese.
- Mlay GS, Manji KP: Respiratory distress syndrome among neonates admitted at Muhimbili Medical Centre, Dar es Salaam, Tanzania. J Trop Pediatr 2000; 46: 303–307.
- Costa S, Rocha G, Leitão A, Guimarães H: Transient tachypnea of the newborn and congenital pneumonia: a comparative study. J Matern Fetal Neonatal Med 2012; 25: 992–994.
- Levine EM, Ghai V, Barton JJ, Strom CM: Mode of delivery and risk of respiratory diseases in newborns. Obstet Gynecol 2001; 97: 439–442.
- Chandrasekhar R, Manchu M, Vijaya L: Clinical study of respiratory distress in newborn. Int J Cont Pediatr 2016; 3: 910–915.
- Miserocchi G: The interstitial and microvascular unit of the lung: from the neonate to the adult. In: Weir EK, Reeves JT, Reeves SI (eds.): Pulmonary Edema. Oxford, Futura (Blackwell), 1998.

In cases of white out lungs, the presence of consolidation favors the diagnosis of RDS, while ruling out TTN. This is a clincher, as white out lungs on CXR often creates a diagnostic dilemma in differentiating TTN from RDS. In such cases, the utility of LUS to identify consolidation reliably will favor the diagnosis of RDS, while the absence of consolidation will favor the diagnosis of TTN.

The distribution of ultrasound findings in RDS and TTN patients is summarized in Tab. 4.

Conclusion

In conclusion, the results of this study demonstrate the ability of lung ultrasound to accurately and reliably diagnose and differentiate RDS and TTN. Lung ultrasound also has other advantages that cannot be replicated by chest radiography. Lung ultrasound can be thus used as an initial screening tool in neonatal intensive care units for lung diseases.

Conflict of interest

None to disclose.