

## Charcot foot in a diabetic patient – clinical and imaging considerations

Editorial comment on: A. Konarzewska, A. Korzon-Burakowska, L. Rzepecka-Wejs, I. Sudół-Szopińska, E. Szurowska, M. Studniarek: *Diabetic foot syndrome: Charcot arthropathy or osteomyelitis? Part I: Clinical picture and radiography*

Adam Greenspan

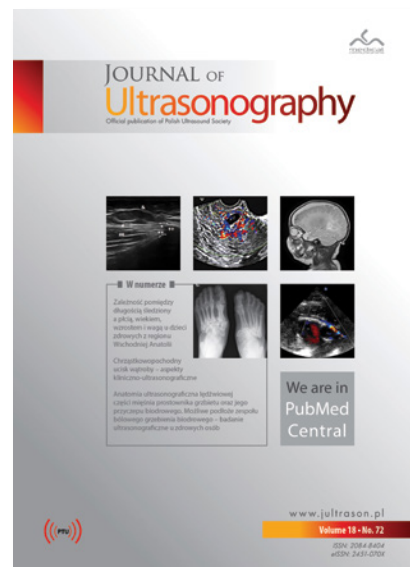
Professor of Radiology and Orthopedic Surgery, University of California, Davis School of Medicine, Sacramento, California, USA

DOI: 10.15557/JoU.2018.0039

One of the common and serious complications of diabetes mellitus is Charcot neuropathy of the foot, the result of decreased sensation and ability to feel temperature and pain combined with repetitive mechanical trauma<sup>(1)</sup>. The Lisfranc joint is the most common site for this arthropathy, although any articulation in the foot and ankle can be affected<sup>(2)</sup>. The hallmark of this deformity is midfoot collapse, known as a “rocker-bottom” foot. The diagnosis of this condition has been challenging even for the most experienced practitioners, including surgeons and radiologists, particularly when the Charcot foot is complicated by osteomyelitis and septic arthritis<sup>(3)</sup>. Radiologic imaging, in addition to clinical examination and laboratory data, plays an important role in differential diagnosis. In their innovative and comprehensive article entitled “Diabetic foot syndrome: Charcot arthropathy or osteomyelitis? Part I: Clinical picture and radiography” by Aleksandra Konarzewska, Anna Korzon-Burakowska, Ludomira Rzepecka-Wejs, Iwona Sudół-Szopińska, Edyta Szurowska, and Michał Studniarek, the authors offer a global approach to this dilemma, discussing in details the clinical findings and conventional radiography in differential diagnosis of diabetic Charcot foot complicated by osteomyelitis<sup>(4)</sup>. Clinical presentation of Charcot neuropathy and osteomyelitis is similar. In addition, both of these conditions may co-exist in the same extremity. Clinically, acute phase of Charcot foot

is characterized by a worm, red, and swollen foot and ankle, findings also typical for infection (osteomyelitis and septic arthritis). Concurrent skin ulcers is also a common finding. Conventional radiography is the primary initial imaging modality for evaluation of the foot in a diabetic patient. It provides information on bone structure, mineralization, and alignment. Furthermore, it may show bone fragmentation, exuberant sclerosis, joint subluxation, soft tissue swelling, joint effusion, and instability – the classic features of neuropathic foot. In case of superimposed osteomyelitis, it may show cortical destruction, osteolytic lesions, and periostitis, and in the later phase – osseous sequestra. Unfortunately, in the early stages of infection, the radiography is not effective as a diagnostic tool. Therefore, advanced imaging techniques should be applied, such as magnetic resonance imaging (MRI), computed tomography (CT), radionuclide bone scan (scintigraphy), and ultrasound (US). The effectiveness of these modalities will be presented by the authors in Part II of their work.

Although the world literature is flooded with articles devoted to the diabetic Charcot foot, the article in reference<sup>(4)</sup> approaches the subject in a unique and very innovative way, not only meticulously discussing the definition, epidemiology, classification, pathogenesis, clinical features, and radiographic findings, but also providing the most up-to-date references pertinent to this, currently being at the cutting edge of research, Charcot neuropathic osteoarthropathy.



## References

1. Chisholm KA, Gilchrist JM: The Charcot joint: A modern neurologic perspective. *J Clin Neuromuscul Dis* 2011; 13: 1–13.
2. Loredó R, Rahal A, Garcia G, Metter D: Imaging of the diabetic foot diagnostic dilemmas. *Foot Ankle Spec* 2010; 3: 249–264.
3. Jones EA, Manaster BJ, May DA, Disler DG: Neuropathic osteoarthropathy: Diagnostic dilemmas and differential diagnosis. *Radiographics* 2000; 20: S279–S293.
4. Konarzewska A, Korzon-Burakowska A, Rzepecka-Wejs L, Sudol-Szopińska I, Szurowska E, Studniarek M: Diabetic foot syndrome: Charcot arthropathy or osteomyelitis? Part I: Clinical picture and radiography. *J Ultrason* 2018; 18: 42–49.