

**Submitted:**  
11.04.2020  
**Accepted:**  
28.04.2020  
**Published:**  
15.06.2020

## Lung ultrasound in a Singapore COVID-19 intensive care unit patient and a review of its potential clinical utility in pandemic

Wee Ming Peh<sup>1</sup>, Steffi Kang Ting Chan<sup>2</sup>, Yi Lin Lee<sup>3</sup>,  
Pravin Shivaji Gare<sup>4</sup>, Vui Kian Ho<sup>4</sup>

<sup>1</sup> Department of General Medicine and Intensive Care Medicine, Seng Kang General Hospital, Singapore

<sup>2</sup> Department of Anaesthesiology, Singapore General Hospital, Singapore

<sup>3</sup> Department of Surgical Intensive Care, Singapore General Hospital, Singapore

<sup>4</sup> Department of Anaesthesiology and Intensive Care Medicine, Seng Kang General Hospital, Singapore

Correspondence: Dr Wee Ming Peh, Department of General Medicine and Intensive Care Medicine, Seng Kang General Hospital, 110 Sengkang E Way, Singapore 544886; e-mail: [peh.wee.ming@singhealth.com.sg](mailto:peh.wee.ming@singhealth.com.sg)

DOI: 10.15557/JoU.2020.0025

### Keywords

COVID-19,  
respiratory failure,  
point-of-care lung  
ultrasound,  
ARDS,  
pneumonia

### Abstract

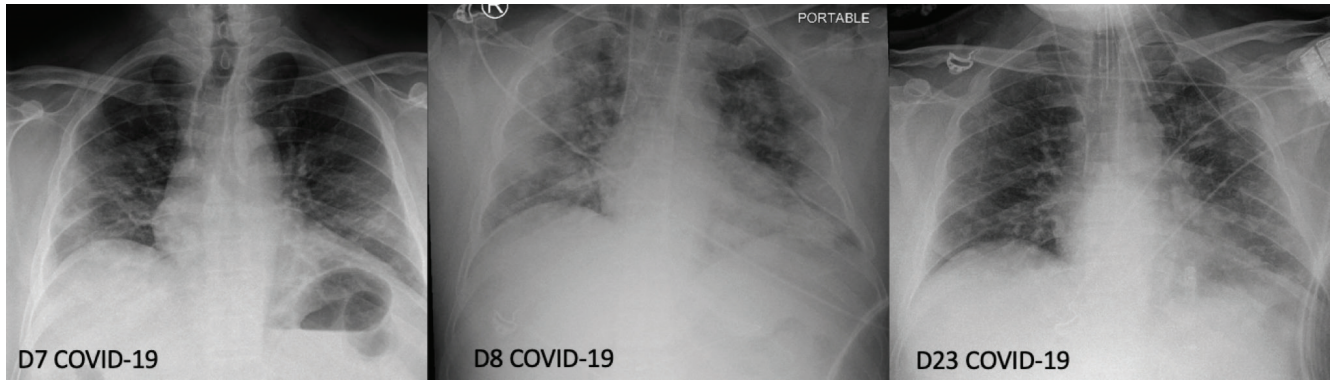
**Background:** Point-of-care bedside lung ultrasound is a diagnostic adjunct in the management of respiratory diseases. We describe the clinical progress and lung ultrasound findings of a Singaporean COVID-19 intensive care unit patient who was diagnosed with COVID-19 infection. **Methods:** The clinical course of one COVID-19 patient managed in the intensive care unit was traced. The patient was diagnosed with COVID-19 virus infection and intubated after developing respiratory failure. Serial point-of-care bedside lung ultrasound was performed by the managing intensivist daily, and correlated with the clinical progress and chest X-ray imaging done for the patient. **Results:** The patient exhibited lung ultrasound findings consistent with that described for viral pneumonias. This included numerous B-lines and subpleural consolidations with disrupted pleural lines distributed symmetrically, predominantly in bilateral upper BLUE points, and lower BLUE points bilaterally. Coalescing B-lines leading on to the development of bilateral “white lung” were associated with worsening acute respiratory distress syndrome. An increased density or reduction of the B-lines was associated with clinical improvement or deterioration, respectively. **Conclusions:** Trained clinicians, who are familiar with point-of-care lung ultrasonography, may consider point-of-care bedside ultrasound as an important adjunct to history and physical examination for the diagnosis and management of COVID-19 when advanced imaging is not available because of logistical reasons or infectious control. This applies in particular to cases where resources are limited, and patient transfers to facilities offering such services may prove hazardous.

## Background

On 31 December 2019, China informed the World Health Organization (WHO) of a novel viral pneumonia in the city of Wuhan (Hubei). The WHO declared the COVID-19 outbreak a public health emergency of international concern (PHEIC) on 30 January 2020. Subsequently, on

12 March 2020, the World Health Organization declared COVID-19 a pandemic<sup>(1)</sup>.

Point-of-care lung ultrasound is performed at the patient's bedside, and offers the trained clinician a rapid imaging adjunct to the chest X-ray and the CT (computed tomography) scanner. This is the first report describing the clinical features



**Fig. 1.** Chest X-ray changes from D7 to D23. Rapid progression to diffuse bilateral infiltrates and with significant improvement with residual left lung infiltrates

and lung ultrasound images of a patient with COVID-19 infection admitted to an intensive care unit in a Singapore regional general hospital. In addition, we provide a brief review of the potential clinical utility, and address the challenges associated with lung ultrasound in the current COVID-19 pandemic.

## Case report

We present the case of a healthy 39-year-old female who complained of 4 days of coughing, exertional dyspnea and fever after returning from Malaysia a week prior. There was no history of travel to China or contacts with any confirmed COVID-19 cases.

The patient was admitted because of tachypnea and hypoxemia (PF(PaO<sub>2</sub>/FiO<sub>2</sub>) ratio 185). There were bilateral lower lobe consolidations on chest X-ray (CXR) (Fig. 1).

On day 4 of admission (D8 illness), because of escalating oxygen requirements, she was intubated and transferred to the intensive care unit (ICU) for further management with lung protective ventilation.

Point-of-care lung ultrasound was performed daily by either one of 2 identified lung ultrasound trained intensivists, using the ultrasound machine (GE Logiq E) curvilinear transducer with the abdominal pre-set in the ICU with a pre-determined protocol.

Three points on each side of the lung were identified for ultrasound imaging<sup>(2)</sup>. These were the upper BLUE point, the lower BLUE point, and the PLAPS points. The BLUE points corresponded to the midclavicular line, anterior-axillary, and posterior-axillary lines that were estimated locations of the upper lobe, middle lobe and lower lobes of each lung, as described by Daniel A. Lichtenstein.

Findings from multiple lung fields using the abdominal pre-set captured from the curvilinear probe were recorded for documentation purposes, and compared between the 2 trained intensivists.

Progress was assessed by the identification of areas of increased involvement and assessment of more or less

B-lines. Areas of interest were further examined with the phase array and linear probe, if needed.

B-lines were the predominant feature in the reported case (Fig. 2 B). An increasing density and distribution of B-lines were associated with deteriorating oxygenation (Fig. 3). The “white lung” ultrasound feature (Fig. 2 A) was frequently found at the peak of clinical deterioration during days 10–12, and associated with the lowest P/F ratio.

Decreasing density and distribution of B-lines were associated with clinical improvement (Fig. 3). The coalescing and reduction of B-lines appear to reflect more closely clinical progression than serial chest X-ray imaging.

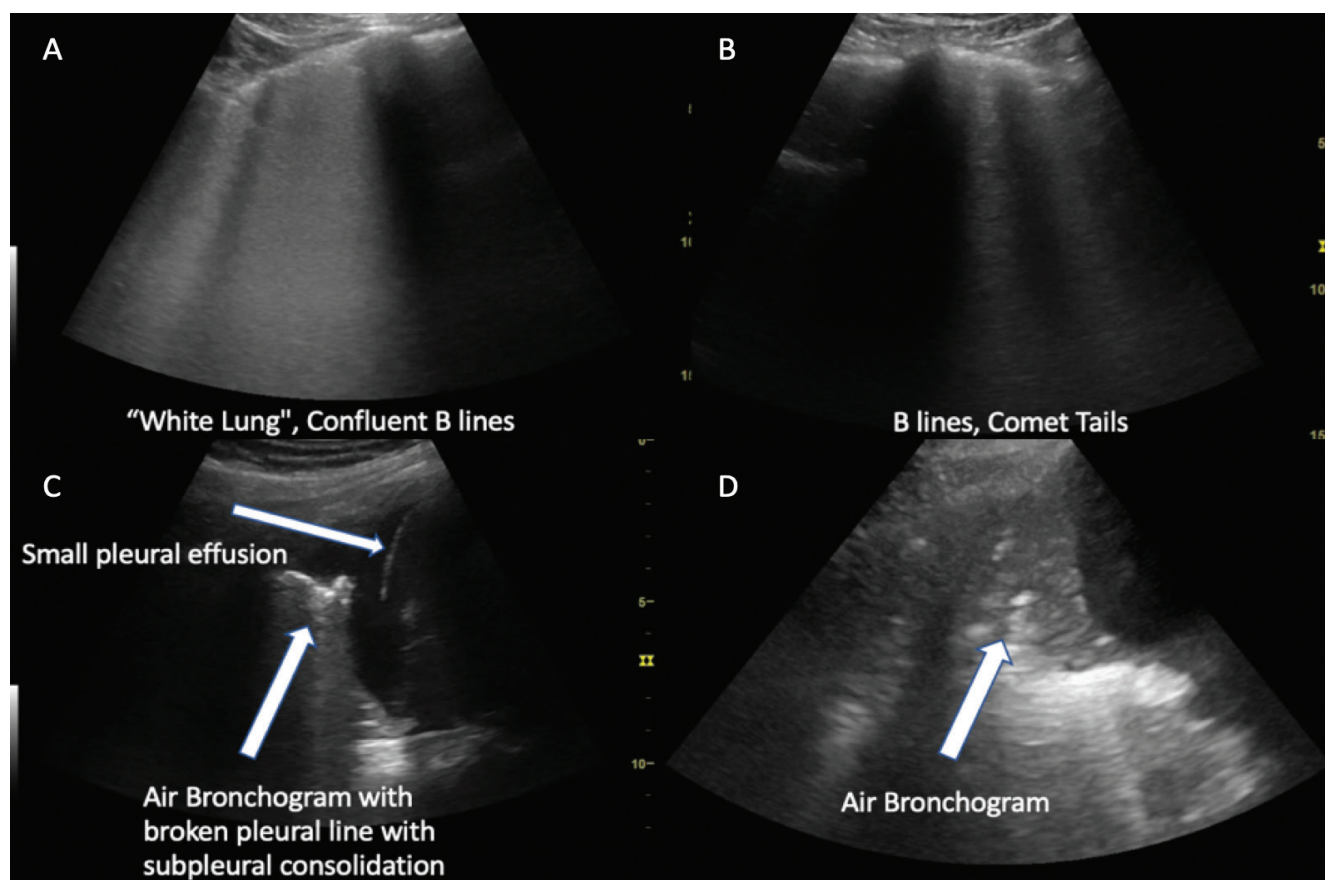
There were fragmented pleural lines associated with diffuse sub-pleural consolidations which projected B-lines (Fig. 4). The COVID-19 virus had a predisposition to the peripheral locations of the lung. Small peripheral consolidations with features of dynamic air bronchogram (Fig. 2 D), hepatization, and the sonographic “shred sign” (Fig. 2 C) were found early after the ICU admission of the patient which resolved first upon recovery before improvement with B-lines.

## Discussion and brief review of current literature

Our report illustrates the clinical features and point-of-care lung ultrasound images in a COVID-19 patient admitted to the ICU.

The main cause of mortality and morbidity in COVID-19 is respiratory failure<sup>(1)</sup>. The role of point-of-care lung ultrasound in evaluating the causes of respiratory failure is well established in literature, and continues to be relevant in the evaluation of respiratory failure in COVID-19 patients<sup>(3–5)</sup>.

In our case report, lung ultrasound features of diffuse and bilateral B-lines with patchy involvement, pleural disruption, fine subpleural consolidations, and white lung features found in our experience are similar to those reported in other limited case studies<sup>(6,7)</sup>. These ultrasound features show good correlation with CT thorax performed in COVID-19 patients<sup>(2,8)</sup>.



**Fig. 2.** White lung and numerous B-lines were predominant features. Increased density and distribution of B-lines were associated with deterioration in clinical signs

Based on our observations and a literature review, there are 4 potential additional roles of point-of-care lung ultrasound in the current COVID-19 crisis.

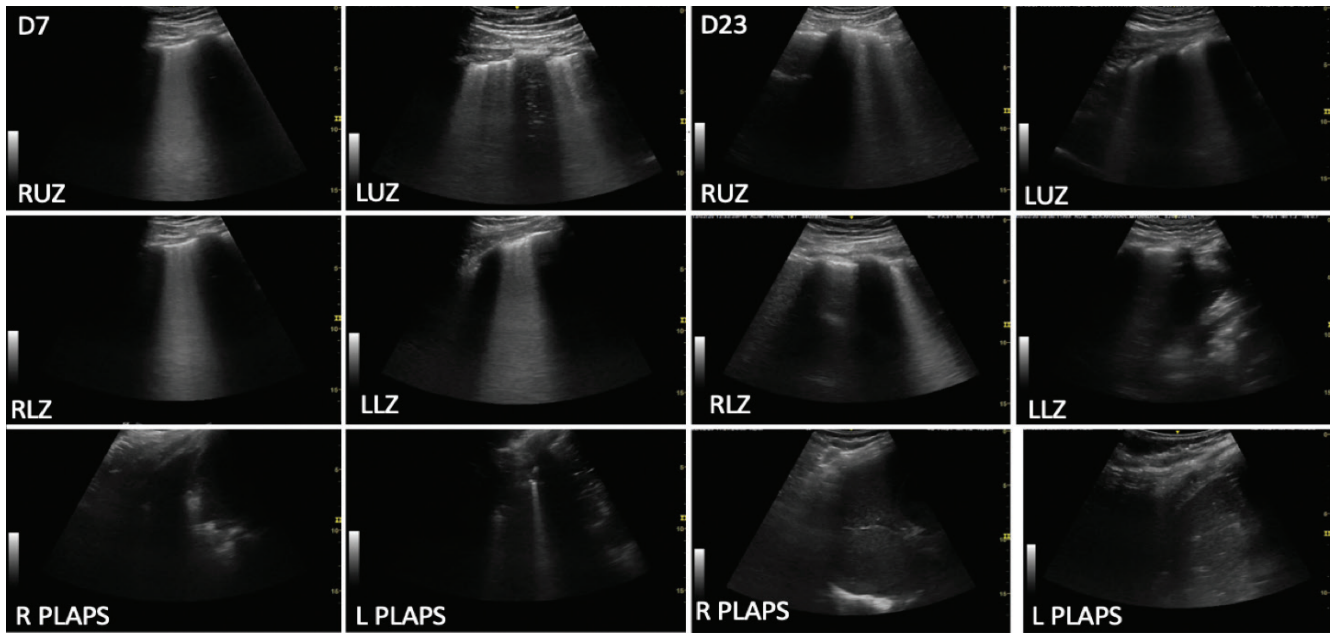
Firstly, lung ultrasound can protect healthcare workers by reducing the usage of chest X-ray and CT scanning<sup>(9)</sup>. A significant percentage (3 to 10%) of COVID-19 patients are healthcare workers<sup>(10,11)</sup>. The ability of an operator to use lung ultrasound in place of chest X-ray/CT to simultaneously examine, acquire and interpret findings at the patient's bedside prevents unnecessary transfers, and reduces the risk of contamination of the facility and exposure of other healthcare workers to COVID-19 patients.

Secondly, lung ultrasound can assist in the triage and assessment of clinical progression. An increasing density of B-lines and involvement of more lung fields have been shown to be correlated with clinical progress, peaking at days 10–12<sup>(2,7,8)</sup>. This finding has been incorporated in the triage protocol in Italian hospitals to assist physicians in identifying ill COVID-19 patients who may benefit from the escalation of care<sup>(12,13)</sup>. Lung ultrasound also shows good correlation in the early identification and assessment of morbidity and mortality in the management of acute respiratory distress syndrome<sup>(14,15)</sup>. The Kigali Modification of the Berlin Criteria for the diagnosis of acute respiratory distress syndrome that utilizes lung ultrasound has been

shown to improve the diagnosis of acute respiratory distress syndrome in resource-limited settings<sup>(16,17)</sup>. In the context of ARDS secondary to COVID-19, the quantification of lung ultrasound via the lung ultrasound score is associated with increased severity and mortality from ARDS<sup>(18)</sup>.

Thirdly, the Surviving Sepsis Campaign Guidelines on the Management of Critically Ill Adults with Coronavirus Disease 2019 (COVID-19) give a strong recommendation for the early initiation of proning for severe hypoxia in COVID-19 pulmonary infection<sup>(19)</sup>. Early proning is associated with a reduction in intubation, and an improvement in mortality in COVID-19 patients, as suggested by a multicenter cohort study by the Chinese, and should ideally be performed in patients with bibasal/posterior involvement of the lung<sup>(20–23)</sup>. Detection of B-lines in the bilateral posterior/basal aspects of the lung may allow physicians to select patients (both awake and intubated) who will benefit most from proning.

Fourthly, a recommendation for the management of critically ill COVID-19 patients is the early use of moderate to high PEEP for lung recruitment, though this needs to be individualized in view of the risk of barotrauma and hemodynamic instability. Reaeration visualized on lung ultrasound can be used as a bedside adjunct to determine PEEP-induced lung recruitment<sup>(24)</sup>.



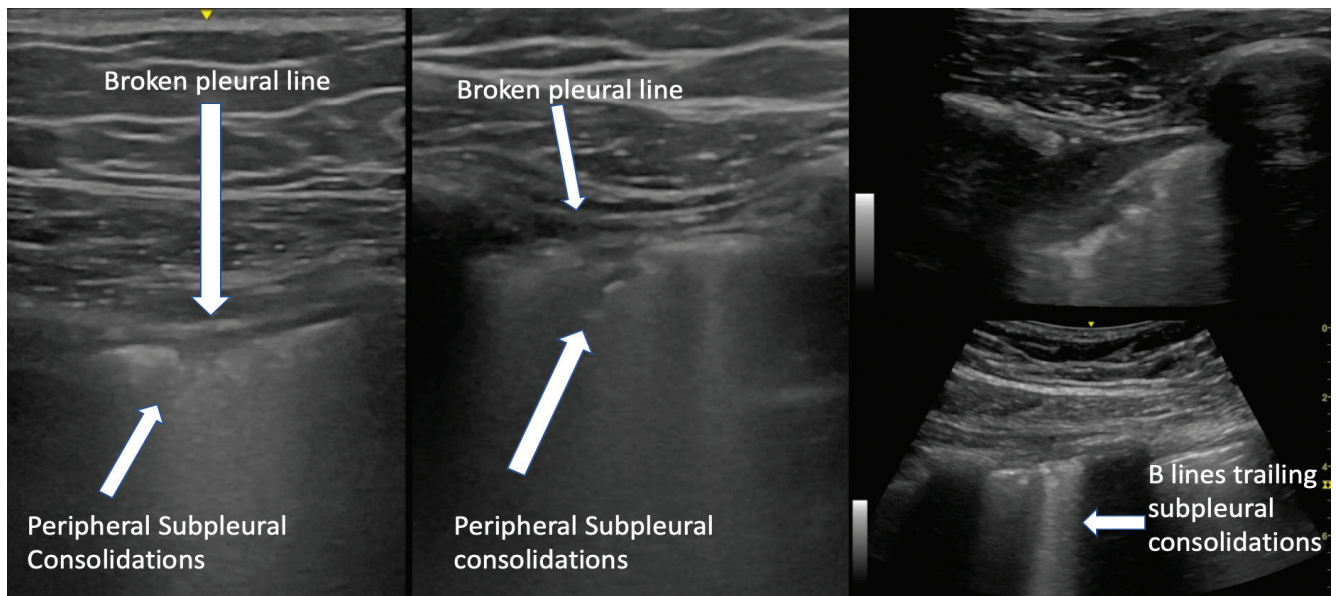
**Fig. 3.** Lung ultrasound findings comparing D7 and D23. Reduction in B-lines leading to resolution of white lung and also recovery of consolidation changes at the bases. R – right, L – left, UZ – upper zone, LZ – lower zone, PLAPS – posterior-lateral alveolar pleural syndrome

Our case report also highlights challenges associated with the widespread use of lung ultrasound in the management of COVID-19 patients.

Firstly, the features of B-lines that may be representative of ground glass changes or interstitial syndrome associated with subpleural consolidations are non-specific. This feature can also be seen in other viral infections such as measles, influenza, and respiratory syncytial virus infection<sup>(25-27)</sup>. Hence, there is insufficient evidence to rely solely on this lung ultrasound finding for the diagnosis of COVID-19.

Secondly, the application of point-of-care ultrasound is operator-dependent, and requires basic training. Even so, learners have found that it is not difficult to acquire basic lung ultrasound skills over a short period of time, with a minimum required number of 25 supervised scans<sup>(28)</sup>.

Thirdly, the precise lung ultrasound protocol best suited to COVID-19 patients has not been established. The BLUE protocol achieves the imaging of a total of 6 lung fields<sup>(4)</sup>. It was chosen, as they were in areas most accessible in our critically ill patients. A disadvantage is that since involvement is patchy, areas of involvement may be missed. Some



**Fig. 4.** Small subpleural consolidations with disruption of the pleural line were a common feature

physicians have used more lung ultrasound fields in patients who are less ill and more ambulatory. A proposed standardized lung ultrasound score by Soldati *et al.* comprising 14 sites with a standardized lung score may be better suited<sup>(12,13)</sup>.

Fourthly, there is no standardized protocol for the disinfection of ultrasound units. This could be overcome by the use of hand-held ultrasound devices that are cheaper and easier to disinfect. However, further research is required on this aspect.

## Conclusion

Our report illustrates the ultrasound findings observed in a COVID-19 patient, and the potential use and challenges

associated with lung ultrasound for physicians who need a diagnostic adjunct for non-specific respiratory symptoms in patients during the current COVID-10 pandemic. Point-of-care lung ultrasound can be considered an alternative imaging modality, replacing chest X-ray and CT scanning, in the triage and ongoing management of patients to protect healthcare workers in resources-constrained settings in the COVID-19 pandemic.

## Conflict of interest

*The authors do not report any financial or personal connections with other persons or organizations which might negatively affect the contents of this publication and/or claim authorship rights to this publication.*

## References

- Wang D, Hu B, Hu C, Zhu F, Liu X, Zhang J *et al.*: Clinical characteristics of 138 hospitalized patients with 2019 novel Coronavirus-infected pneumonia in Wuhan, China. *JAMA* 2020. Doi: 10.1001/jama.2020.1585.
- Lei J, Li J, Li X, Qi X: CT imaging of the 2019 novel Coronavirus (2019-nCoV) pneumonia. *Radiology* 2020; 295: 18. Doi: 10.1148/radiol.2020200236.
- Moore CL, Copel JA: Point-of-care ultrasonography. *N Engl J Med* 2011; 364: 749–757. Doi: 10.1056/nejmra0909487.
- Lichtenstein DA, Mezière GA: The BLUE-points: three standardized points used in the BLUE-protocol for ultrasound assessment of the lung in acute respiratory failure. *Crit Ultrasound J* 2011; 3: 109–110.
- Lichtenstein DA: Lung ultrasound in the critically ill. *Ann Intensive Care* 2014; 4: 1. Doi: 10.1186/2110-5820-4-1.
- Peng QY, Wang XT, Zhang LN, Chinese Critical Care Ultrasound Study Group (CCUSG): Findings of lung ultrasonography of novel coronavirus pneumonia during the 2019–2020 epidemic. *Intensive Care Med* 2020; 46: 849–850. Doi: 10.1007/s00134-020-05996-6.
- Huang Y, Wang S, Liu Y, Zhang Y, Zheng C *et al.*: A preliminary study on the ultrasonic manifestations of peripulmonary lesions of non-critical novel Coronavirus pneumonia (COVID-19). *SSRN* 2020, February 26. Available from: [https://papers.ssrn.com/sol3/papers.cfm?abstract\\_id=3544750](https://papers.ssrn.com/sol3/papers.cfm?abstract_id=3544750).
- Pan F, Ye T, Sun P, Gui S, Liang B, Li L *et al.*: Time course of lung changes on chest CT during recovery from 2019 novel Coronavirus (COVID-19) pneumonia. *Radiology* 2020. Doi: 10.1148/radiol.2020200370.
- Broggi E, Bignami E, Sidoti A, Shawar M, Gargani L, Vetrugno L *et al.*: Could the use of bedside lung ultrasound reduce the number of chest X-rays in the intensive care unit? *Cardiovasc Ultrasound* 2017; 15: 23. Doi: 10.1186/s12947-017-0113-8.
- Wang J, Zhou M, Liu F: Reasons for healthcare workers becoming infected with novel coronavirus disease 2019 (COVID-19) in China. *J Hosp Infect* 2020; 105: 100–101. Doi: 10.1016/j.jhin.2020.03.002.
- Anelli F, Leoni G, Monaco R, Nume C, Rossi RC, Marinoni G *et al.*: Italian doctors call for protecting healthcare workers and boosting community surveillance during covid-19 outbreak. *BMJ* 2020. Doi: 10.1136/bmj.m1254.
- Soldati G, Smargiassi A, Inchingolo R, Buonsenso D, Perrone T, Briganti DF *et al.*: Proposal for international standardization of the use of lung ultrasound for COVID-19 patients; a simple, quantitative, reproducible method. *J Ultrasound Med* 2020. Doi: 10.1002/jum.15285.
- Soldati G, Smargiassi A, Inchingolo R, Buonsenso D, Perrone T, Briganti DF *et al.*: Is there a role for lung ultrasound during the COVID-19 pandemic? *J Ultrasound Med* 2020. Doi: 10.1002/jum.15284.
- Xirouchaki N, Magkanas E, Vaporidi K, Kondili E, Plataki M *et al.*: Lung ultrasound in critically ill patients: comparison with bedside chest radiography. *Intensive Care Med* 2011; 37: 1488–1493. Doi: 10.1007/s00134-011-2317-y.
- See KC, Ong V, Tan YL, Sahagun J, Taculod J: Chest radiography versus lung ultrasound for identification of acute respiratory distress syndrome: a retrospective observational study. *Crit Care* 2018; 22: 203. Doi: 10.1186/s13054-018-2105-y.
- Goh KJ, Choong MC, Cheong EH, Kalimuddin S, Duu Wen S, Phua GC *et al.*: Rapid progression to acute respiratory distress syndrome: review of current understanding of critical illness from COVID-19 infection. *Ann Acad Med Singapore* 2020; 49: 1–9.
- Riviello ED, Kiviri W, Twagirumugabe T, Mueller A, Banner-Goodspeed VM, Officer L *et al.*: Hospital incidence and outcomes of the acute respiratory distress syndrome using the Kigali modification of the Berlin definition. *Am J Respir Crit Care Med* 2016; 19: 52–59.
- Li L, Yang Q, Li L, Guan J, Liu Z, Han J *et al.*: The value of lung ultrasound score on evaluating clinical severity and prognosis in patients with acute respiratory distress syndrome. *Zhonghua Wei Zhong Bing Ji Jiu Yi Xue* 2015; 27: 579–584. Doi: 10.3760/cma.j.issn.2095-4352.2015.07.008.
- Alhazzani W, Møller, MH, Arabi YM, Loeb M, Gong MN, Fan E *et al.*: Surviving Sepsis Campaign: guidelines on the management of critically ill adults with Coronavirus Disease 2019 (COVID-19). *Intensive Care Med* 2020; 46: 854–887. Doi: 10.1007/s00134-020-06022-5.
- Ding L, Wang L, Ma W, He H: Efficacy and safety of early prone positioning combined with HFNC or NIV in moderate to severe ARDS: a multi-center prospective cohort study. *Crit Care* 2020; 24: 28. Doi: 10.1186/s13054-020-2738-5.
- Wang X, Ding X, Zhang H, Chen H, Su L, Liu D: Lung ultrasound can be used to predict the potential of prone positioning and assess prognosis in patients with acute respiratory distress syndrome. *Crit Care* 2020; 20: 385. Doi: 10.1186/s13054-016-1558-0.
- Gattinoni L, Busana M, Giosa L, Macri M, Quintel M: Prone positioning in acute respiratory distress syndrome. *Sem Respir Crit Care Med* 2019; 40: 94–100. Doi: 10.1055/s-0039-1685180.
- Agrawal SP, Goel AD: Prone position ventilation in acute respiratory distress syndrome: an overview of the evidences. *Indian J Anaesth* 2015; 59: 246–248. Doi: 10.4103/0019-5049.155004.
- Bouhemad B, Brisson H, Le-Guen M, Arbelot C, Lu Q, Rouby JJ: Bedside ultrasound assessment of positive end-expiratory pressure-induced lung recruitment. *Am J Respir Crit Care Med* 2011; 183: 341–347. Doi: 10.1164/rccm.201003-0369oc.
- Volpicelli G, Frascisco M: Sonographic detection of radio-occult interstitial lung involvement in measles pneumonia. *Am J Emerg Med* 2009; 27: 128.e1–128.e3.
- Tsung JW, Kessler DO, Shah VP: Prospective application of clinician performed lung ultrasonography during the 2009 H1N1 influenza A pandemic: distinguishing viral from bacterial pneumonia. *Crit Ultrasound J* 2012; 4: 16.
- Testa A, Soldati G, Copetti R, Giannuzzi R, Portale G, Gentiloni-Silveri N: Early recognition of the 2009 pandemic influenza A (H1N1) pneumonia by chest ultrasound. *Crit Care* 2012; 16: R30.
- Arbelot C, Dexheimer Neto FL, Gao Y, Brisson H, Chunyao W, Lv J *et al.*: Lung ultrasound in emergency and critically ill patients. *Anesthesiology* 2020; 132: 899–907. Doi: 10.1097/aln.0000000000003096.