

Submitted:
10.06.2020
Accepted:
27.08.2020
Published:
18.12.2020

Evaluation of the snowing-like ultrasonographic features of intraosseous jaw pathologies

Ibrahim Sevki Bayrakdar¹, Ahmet Berhan Yılmaz²,
Fatma Akkoca Kaplan³, Elif Bilgir⁴, Kaan Orhan⁵

¹ Associate Professor, Department of Oral and Maxillofacial Radiology, Faculty of Dentistry, Eskisehir Osmangazi University, Eskişehir-Turkey

² Professor, Department of Oral and Maxillofacial Radiology, Faculty of Dentistry, Ataturk University, Erzurum-Turkey

³ Research Assistant, Department of Oral and Maxillofacial Radiology, Faculty of Dentistry, Eskisehir Osmangazi University, Eskişehir-Turkey

⁴ Assistant Professor, Department of Oral and Maxillofacial Radiology, Faculty of Dentistry, Eskisehir Osmangazi University, Eskişehir-Turkey

⁵ Professor, Department of Oral and Maxillofacial Radiology, Faculty of Dentistry, Ankara University, Ankara-Turkey

Correspondence: Dr. Ibrahim Sevki Bayrakdar, Department of Oral and Maxillofacial Radiology, Faculty of Dentistry, Eskisehir Osmangazi University, 26240, Eskişehir, Turkey; tel.: 0090 222 2391303, fax: 0090 222 2391273, e-mail: ibrahimsevikbayrakdar@gmail.com

DOI: 10.15557/JoU.2020.0053

Keywords

intraosseous
jaw pathology,
snowflakes,
ultrasonography

Abstract

Aim of the study: Ultrasonographic examination of intraosseous jaw pathologies may reveal interesting incidental, mobile hyperechoic particles (“snowflakes”) in anechoic areas. Purpose of this study is to explain and discuss this snowing-like ultrasonographic feature of intraosseous jaw pathologies. **Material and methods:** This study included 113 patients admitted to our clinic for examination: 43 (38.05%) males and 70 (61.9%) females with a mean age of 34.9 ± 17.2 years (range: 6–72 years). A total of 120 intraosseous lesions were evaluated prior to surgery using ultrasonography; these included non-neoplastic, odontogenic, and non-odontogenic lesions. **Results:** In total, 5 (4.1%) of the 120 lesions exhibited snowing-like feature on ultrasonography, including 2 (1.6% of total) of 3 incisive canal cysts, 2 (1.6% of total) of 7 dentigerous cysts, and 1 (0.8% of total) of 19 odontogenic keratocysts. **Conclusions:** Snowflakes evident on ultrasonography of intraosseous jaw lesions may be specific to certain pathologies. Future studies correlating radiologic and pathologic features of intraosseous jaw lesions should focus on ultrasonographic snowing-like appearance in different types of lesions and explore why they occur.

Introduction

Intraosseous odontogenic, non-odontogenic, neoplastic, and non-neoplastic pathologies are common in the maxilla and mandible^(1,2). Imaging data are required for diagnosis, treatment planning, and follow-up⁽¹⁾. Clinical examination is used first to diagnose intra- and extra-bone jaw lesions, followed by radiological evaluation^(3,4). Traditional radiography modalities (orthopantomography, and occlusal and

periapical radiography) are primarily used to evaluate maxillofacial lesions, but these methods have disadvantages including magnification errors, distortion, and structural misrepresentation⁽⁵⁾. Although computed tomography (CT) and magnetic resonance imaging (MRI) are useful for assessment of jawbone lesions, they have several disadvantages. Low-dose cone-beam CT (CBCT) is particularly suited for evaluation of the maxillofacial region⁽⁶⁾. However, both CT and CBCT expose patients to ionizing radiation and yield

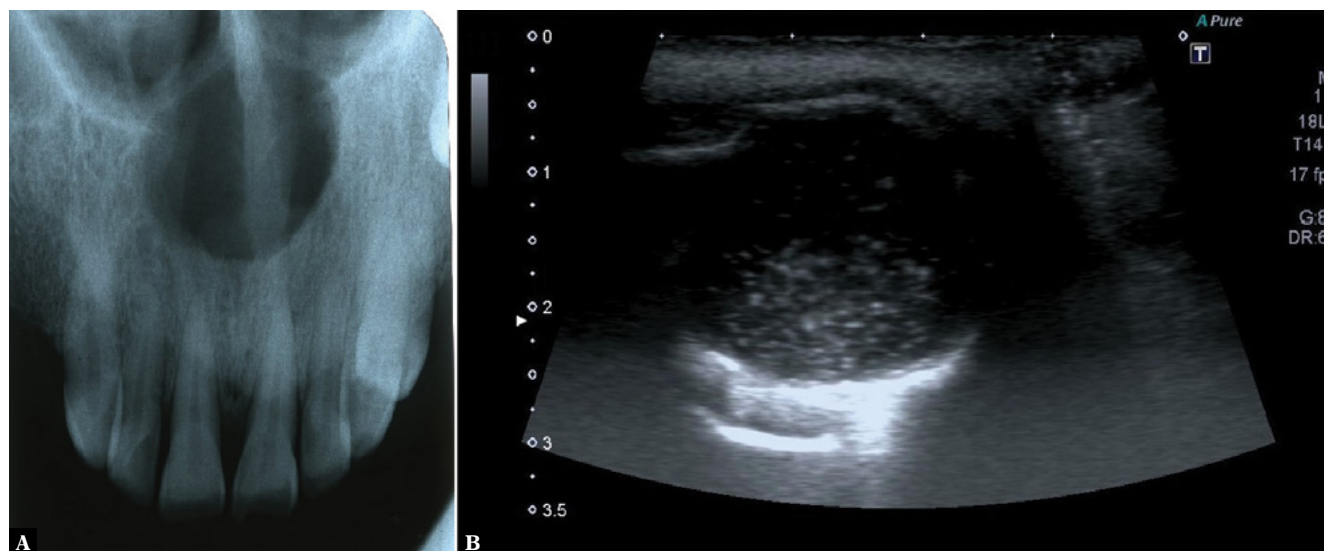


Fig. 1. A. Occlusal radiographs show that well-defined radiolucent lesion in anterior maxilla. (incisive duct cyst) **B.** The snowflakes-like appearance of intraosseous lesions on ultrasonography (incisive duct cyst)

limited data on lesional contents. MRI does not employ ionizing radiation but is the best-suited modality for imaging of intracranial and soft-tissue lesions. In addition, the equipment is costly, and the screening time is long; moreover, this imaging technique is contraindicated in claustrophobic patients, and in those with certain types of surgical clips, pacemakers, and cochlear implants⁽⁷⁾. Ultrasonography (US) is a new and promising diagnostic imaging modality for evaluation of head and neck lesions in lymph nodes and salivary glands, as well as facial bone fractures⁽⁸⁾. US reveals the contents of intraosseous jaw lesions^(1,2,8–11), and currently plays auxiliary and supportive roles. US enhances our understanding of lesional histology⁽¹²⁾. Also, US is safe; no ionizing radiation is used. US is indicated for pregnant and pediatric patients, being simple, painless, repeatable, non-invasive, and economical. US provides useful information on intraosseous jaw lesions^(1,2,8–11).

In our previous study on intraosseous US pathologies, we sometimes observed mobile hyperechoic particles in anechoic areas⁽⁹⁾ which we termed “snowflakes appearance”, have not been discussed previously. The purpose of this study is to explain and discuss this incidental snowing-like appearance and describe the patient populations that exhibit them.

Materials and methods

Patient selection

Preoperative US images of 120 intraosseous jaw lesions from 113 patients admitted to our clinic were reviewed retrospectively. The study group consisted of 43 (38.05%) males and 70 (61.9%) females, with a mean age of 34.9 ± 17.2 years (range: 6–72 years); all patients provided written informed consent. This retrospective study adhered to all relevant principles of the Declaration of Helsinki.

The Clinical Research Ethics Committee of the Eskisehir Osmangazi University Faculty of Medicine approved the study (permit no. 13; October 8, 2019). Biopsy data were collected prior to surgery. Lesional diagnoses were histopathologically confirmed.

Imaging/US devices

Two US devices were used to evaluate pathologies. Extra-oral sonograms were obtained in the transverse and longitudinal planes using both an Aplio 300 device (Toshiba Corporation, Tokyo, Japan) fitted with an 8-MHz linear array transducer and a Mindray DC N3 device (Shenzhen, China) fitted with a 4–10-MHz linear array transducer. To ensure standardization of all US examinations, patients sat upright with the sagittal plane perpendicular to the floor and the occlusal plane of the jaw with the localized lesion parallel to the floor.

Snowing-like appearance

Mobile hyperechoic particles like snowflakes in anechoic areas were encountered as incidentally in ultrasonographic images. This appearance resembles a snowfall. Because of this, this view was named the “Snowing-like appearance” inspired snowing.

Results

The 120 pathologies included neoplastic, non-neoplastic, odontogenic, and non-odontogenic lesions. Five (4.1%) lesions exhibited snowflakes (Fig. 1 and Video 1): 2 (1.6% of total) (localized maxillary anterior region and histopathological examinations show that microscopically, cyst lined by ciliated pseudostratified columnar epithelium) of 3 incisive canal cysts, 2 (1.6% of total) (localized maxillary anterior region and histopathological examinations show that nonkeratinized, stratified

Tab. 1. The snowing-like features of various intraosseous jaw pathologies

Intraosseous jaw pathologies	Incisive duct cyst	Dentigerous cyst	Odontogenic keratocyst
Total pathologies	3	7	19
Number of snowflakes appearance	2	2	1

Tab. 2. Characteristics of the lesions with the appearance of snowing-like

	Lesion localization	Lesion size	Content of the lesion
Incisive duct cyst (1)	Maxilla-anterior	25.2 × 23.2 × 24.6 mm	Cystic
Incisive duct cyst (2)	Maxilla-anterior	29.8 × 27.6 × 32.4 mm	Cystic
Dentigerous cyst (1)	Maxilla-anterior	32.5 × 23.1 × 23.8 mm	Cystic
Dentigerous cyst (2)	Maxilla-anterior	26.7 × 23.2 × 25.3 mm	Cystic
Odontogenic keratocyst	Maxilla-anterior-canine-premolar	33.1 × 30.1 × 36.1 mm	Cystic

squamous epithelium) of 7 dentigerous cysts, and 1 (localized maxillar anterior-canine-premolar region and histopathological examination shows that microscopically, cyst lined by mature squamous epithelium and parakeratotic keratinaceous debris) (0.8% of total) of 19 odontogenic keratocysts (Tab. 1). All these lesions had cystic content. Characteristics of the lesions with the appearance of snowing-like were summarized Tab. 2.

Discussion

Many studies have used US to evaluate intraosseous lesions, principally in terms of lesional contents, margins, and vascularity^(1,2,8-11) Lauria *et al.*⁽¹⁾ compared the US and histopathological findings of 72 intraosseous jaw lesions. US revealed lesional contents prior to surgery⁽¹⁾. However, no specific data were provided. Ishii *et al.* used US for preoperative evaluation of palatal salivary gland tumors⁽⁸⁾. Cotti *et al.*⁽¹³⁾ employed US for differential diagnosis of cystic lesions and granulomas among 11 periapical lesions. The US and histopathological findings were consistent⁽¹³⁾. Subsequently, Gundappa *et al.*⁽¹⁴⁾ showed that US differentiated cysts from granulomas⁽¹⁴⁾. Yee *et al.*⁽¹¹⁾ used US to evaluate osteosarcomas, describing a pathognomic “sunray appearance”. This was the first report on the US features of mandibular osteosarcomas. The importance of early US in terms of detecting pathognomic images was emphasized. Although US is not definitively diagnostic of bone pathologies, early US is valuable⁽¹¹⁾. Preoperatively, Sumer *et al.*⁽²⁾ used power Doppler US to accurately evaluate the vascularity of 22 intraosseous lesions⁽²⁾. Bayrakdar *et al.*⁽⁹⁾ employed US to preoperatively examine 89 intraosseous lesions. Histopathological and US findings were compared in this study. US sometimes revealed hyperechoic snowflakes in anechoic areas, which may be epithelial or keratin remnants, or dead fragments of previously infected tissues. They observed snowflakes in 3 of 89 intraosseous lesions, including 2 (2.3%) incisive canal cysts and 1 (1.1%) odontogenic

keratocyst. They also observed snowflakes in 1 of 18 odontogenic keratocysts and 2 of 3 incisive duct cysts⁽⁹⁾. In this present study, we observed this phenomenon in 2 dentigerous cysts in addition to these lesions. Snowflakes were not present in all dentigerous or incisive duct cysts, or odontogenic keratocysts, possibly because US does not reveal all features of intraosseous lesions. Thick cortical bone may complicate evaluation of lesional contents; this is the most important limitation of our study. Although we evaluated 120 intraosseous jaw lesions, all were above a certain size, where size may influence lesional content. We observed snowflakes in only five lesions. These lesions we encountered with snowing-like appearance had sizes greater than 20 mm. Maybe, smaller lesions do not mature enough containing predominantly fluid, maybe it was too early in lesion development for the “snowing” appearance to be observed.

Ferreira *et al.*⁽¹⁵⁾, in a preliminary study on pig jaws, showed that lesions can be examined via US if the cortical bone is thin⁽¹⁵⁾. Musu *et al.*⁽¹⁶⁾ confirmed that US significantly assisted differential diagnosis of jawbone lesions⁽¹⁶⁾. However, the snowflakes, as incidental findings, have not been previously evaluated. A dentigerous cyst is covered with a nonkeratinized, stratified squamous epithelium reflecting proliferation of the reduced enamel epithelium⁽¹⁷⁾. A nasopalatine canal cyst reflects proliferation of epithelial remnants of the nasopalatine canal, the epithelium of which is mostly squamous⁽¹⁸⁾. An odontogenic keratocyst is lined with keratinized epithelium from residual cells of the dental lamina⁽¹⁹⁾. Thus, the snowflakes may be epithelial, infective, or keratin-like remnants. This appearance could influence diagnosis based on ultrasonographic examination. It could be a clue whether it is infected or not, includes keratin-like remnants or epithelial remnant. It can help the clinical diagnosis of the lesions.

However, we studied only a few lesions; this is a limitation of our work that we will address in future studies. Besides, we used two different linear array transducers for imaging of jaw lesions. Frequency of both probes was relatively low when considering examinations of small parts, even if we get the chance to view of snowing-like appearance in imaging of the intraosseous jaw lesions. Future studies should be eliminated this limitation using high frequency transducers.

Conclusions

The interesting snowflakes incidentally noted on US may be specific for certain pathologies, indicative of epithelial, infective, or keratin remnants. Future studies correlating pathology and radiology findings should aim to clarify when and why snowflakes occur, and which lesions are involved.

Conflict of interest

Authors do not report any financial or personal connections with other persons or organizations, which might negatively affect the contents of this publication and/or claim authorship rights to this publication.

References

- Lauria L, Curi MM, Chammas MC, Pinto DS, Torloni H: Ultrasonography evaluation of bone lesions of the jaw. *Oral Surg Oral Med Oral Pathol Oral Radiol Endod* 1996; 82: 351–357.
- Sumer AP, Danaci M, Ozen Sandıkçı E, Sumer M, Celenk P: Ultrasonography and Doppler ultrasonography in the evaluation of intraosseous lesions of the jaws. *Dentomaxillofac Radiol* 2009; 38: 23–27.
- Weber AL: Imaging of cysts and odontogenic tumors of the jaw. Definition and classification. *Radiol Clin North Am* 1993; 31: 101–120.
- Underhill TE, Katz JO, Pope Jr TL, Dunlap CL: Radiologic findings of diseases involving the maxilla and mandible. *AJR Am J Roentgenol* 1992; 159: 345–350.
- Boeddinghaus R, Whyte A: Current concepts in maxillofacial imaging. *Eur J Radiol* 2008; 66: 396–418.
- Whaites E: *Essentials of dental radiography and radiology*. 4th Edition, Churchill Livingstone Elsevier, London 2007.
- Niraj LK, Patthi B, Singla A, Gupta R, Ali I, Dhama K *et al.*: MRI in dentistry-A future towards radiation free imaging-systematic review. *J Clin Diagn Res* 2016; 10: ZE14–ZE19.
- Ishii J, Nagasawa H, Wadamori T, Yamashiro M, Ishikawa H, Yamada T *et al.*: Ultrasonography in the diagnosis of palatal tumors. *Oral Surg Oral Med Oral Pathol Oral Radiol Endod* 1999; 87: 39–43.
- Bayraktar IS, Yılmaz AB, Çağlayan F, Ertas U, Gundogdu C, Gumussoy I: Cone beam computed tomography and ultrasonography imaging of benign intraosseous jaw lesion: a prospective radiopathological study. *Clin Oral Investig* 2018; 22: 1531–1539.
- Shahidi S, Shakibafard A, Zamiri B, Mokhtare MR, Houshyar M, Mahdian S: The feasibility of ultrasonography in defining the size of jaw osseous lesions. *J Dent* 2015; 16: 335–340.
- Ng SY, Songra A, Ali N, Carter JLB: Ultrasound features of osteosarcoma of the mandible – a first report. *Oral Surg Oral Med Oral Pathol Oral Radiol Endod* 2001; 92: 582–586.
- El-Silimy O, Corney C: The value of sonography in the management of cystic neck lesions. *J Laryngol Otol* 1993; 107: 245–251.
- Cotti E, Campisi G, Ambu R, Dettori C: Ultrasound real-time imaging in the differential diagnosis of periapical lesions. *Int Endod J* 2003; 36: 556–563.
- Gundappa M, Ng S, Whaites E: Comparison of ultrasound, digital and conventional radiography in differentiating periapical lesions. *Dentomaxillofac Radiol* 2006; 35: 326–333.
- Ferreira TL, Costa ALE, Tucunduva MJA, Tucunduva-Neto RR, Shinohara EH, de Freitas CF: Ultrasound evaluation of intra-osseous cavity: a preliminary study in pig mandibles. *J Oral Biol Craniofac Res* 2016; 6: S14–S17.
- Musu D, Rossi-Fedele G, Campisi G, Cotti E: Ultrasonography in the diagnosis of bone lesions of the jaws: a systematic review. *Oral Surg Oral Med Oral Pathol Oral Radiol* 2016; 122: e19–e29.
- Regezi JA, Sciubba J, Jordan RC: *Oral Pathology: Clinical Pathologic Correlations*. Elsevier Health Sciences; 2016.
- Anneroth G, Hall G, Stuge U: Nasopalatine duct cyst. *Int J Oral Maxillofac Surg* 1986; 15: 572–580.
- Brannon RB: The odontogenic keratocyst: a clinicopathologic study of 312 cases. Part II. Histologic features. *Oral Surg Oral Med Oral Pathol* 1977; 43: 233–255.