

Submitted:
08.01.2021
Accepted:
16.03.2021
Published:
16.08.2021

MV-Flow and LumiFlow: a new Doppler tool for assessing the development of fetal brain vascularization in late-first/early-second trimester of pregnancy

Alessandro Giuffrida¹, Eduardo Félix Martins Santana^{2,3,4},
Edward Araujo Júnior^{4,5}

¹ Department of Prenatal Diagnosis, Center of Prenatal Diagnosis G2 Medica – Catania, Italy

² Department of Women's Health, Albert Einstein School of Medicine, São Paulo-SP, Brazil

³ Fetal Medicine Unit, Department of Perinatology, Albert Einstein Hospital, São Paulo-SP, Brazil

⁴ Department of Obstetrics, Paulista School of Medicine – Federal University of São Paulo (EPM-UNIFESP), São Paulo-SP, Brazil

⁵ Medical Course, Municipal University of São Caetano do Sul (USCS), São Paulo-SP, Brazil

Correspondence: Prof. Edward Araujo Júnior, PhD, Rua Belchior de Azevedo, 156 apto. 111 Torre Vitoria, CEP 05089-030, São Paulo – SP, Brazil; tel./fax: +55 11 37965944, e-mail: araujojred@terra.com.br

DOI: 10.15557/JoU.2021.0042

Early prenatal assessment of the development of cerebral vascularization represents a real challenge in the field of fetal medicine. A detailed identification of those vessels and their formation carries great importance, especially in the late-first/early-second trimester of pregnancy, because an early identification of defects can be largely beneficial for treatment planning. By using transvaginal ultrasonography in the second and third trimesters, Monteagudo *et al.* described the detailed antenatal visualization of the fetal brain for the first time in 1991⁽¹⁾. Despite several difficulties, such as limited identification of all the brain vessels, subsequent studies that advanced the technique with the use of power Doppler continued to be reported in the 1990s⁽²⁾.

Pooh *et al.*⁽³⁾ and Chang *et al.*⁽⁴⁾ described fetal brain morphology and circulation by transvaginal 3D sonography and power Doppler techniques, thereby improving the identification and management of abnormalities in the central nervous system. The technique also proved to be useful for the assessment of growth-restricted fetuses and demonstrated the “frontal brain sparing effect” when the anterior cerebral artery revealed vasodilatation⁽⁵⁾. In 2012, Hata *et al.*⁽⁶⁾ reported the evaluation of fetal brain by 3D transvaginal power Doppler imaging at 10 to 13 weeks of gestation, showing an important assessment of early fetal brain perfusion. The volume of fetal brain and the analysis of structures such as the pericallosal artery are described below; this revolutionary technique expanded the possibilities of neurosonographic studies^(7,8).

Recently, Dall’Asta *et al.*⁽⁹⁾ described the application of a new highly sensitive low-velocity flow Doppler technique in the specialized assessment of the posterior fossa. The study reported an indirect evaluation of the insertion of the cerebellar tentorium in the second trimester with images of high quality and resolution. New Doppler technologies have been developed for a better evaluation of microvascularization in the structures that present a slow flow as well as detailed vascular connections.

MV-flow allows a detailed view of blood flow at low speeds with high sensitivity and resolution in relation to the surrounding tissues. In this manner, it is possible to detect the micro-blood flow (microfluidic channel) in the tissues and organs. LumiFlow is an advanced post-processing and shading technique in which the images can be processed by placing a light source in the right position to create shadows and produce a three-dimensional (3D) effect. LumiFlow allows the 3D visualization of the vascular image in real time. The flow limits appear relatively darker and create a clear distinction between the blood vessels. In addition, the technique removes background noise in a highly effective manner.

By using the Hera W10 apparatus (Samsung Co., Seoul, South Korea), the study employed both the MV-Flow and LumiFlow to enable a clear assessment of the vascular anatomy of the fetal brain in the late-first/early-second trimester of pregnancy. These new Doppler technologies clearly visualized the development of midline cerebral vascularization in a fetus at 16 weeks of gestation (Fig. 1), as well as the development of the circle of Willis vascularization in a fetus at 12 + 4 weeks of gestation (Fig. 2).

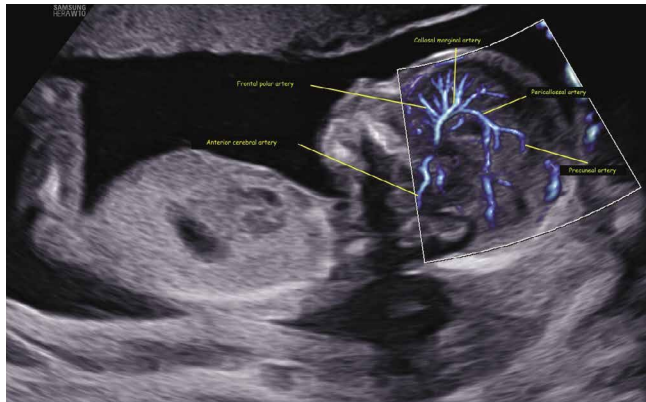


Fig. 1. Sagittal view of the fetal brain at 16 weeks of gestation showing detailed midline vascular neuroanatomy using both MV-Flow and LumiFlow: frontal polar artery, anterior cerebral artery, callosal marginal artery, pericallosal artery, and precuneal artery

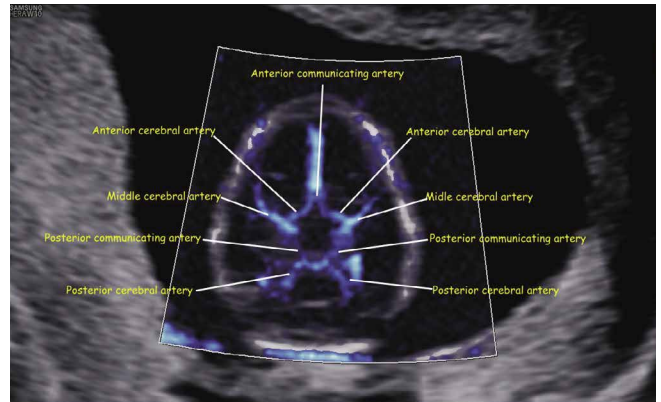


Fig. 2. Axial view of the fetal brain at 12 + 4 weeks of gestation showing detailed vascular neuroanatomy of the circle of Willis using both MV-Flow and LumiFlow: anterior and posterior communicating arteries; anterior, middle, and posterior cerebral arteries

To the best of our knowledge, there are no previous reports that used both MV-Flow and LumiFlow to assess the fetal brain vascularization in the late-first/early-second trimester of pregnancy. In summary, both MV-Flow and LumiFlow can improve the evaluation of the development of fetal brain vessels, especially in detailed screening for vascular congenital anomalies.

Conflict of interest

Authors do not report any financial or personal connections with other persons or organizations, which might negatively affect the contents of this publication and/or claim authorship rights to this publication.

References

1. Monteagudo A, Ressus ML, Timor-Trisch IE: Imaging the fetal brain in the second and third trimesters using transvaginal sonography. *Obstet Gynecol* 1991; 77: 27–32.
2. Pooh RK, Aono T: Transvaginal power Doppler angiography of the fetal brain. *Ultrasound Obstet Gynecol* 1996; 8: 417–421.
3. Pooh RK, Pooh KH: The assessment of fetal brain morphology and circulation by transvaginal 3D sonography and power Doppler. *J Perinat Med* 2002; 30: 48–56.
4. Chang CH, Yu CH, Ko HC, Chen CL, Chang FM: Three-dimensional power Doppler ultrasound for the assessment of the fetal brain blood flow in normal gestation. *Ultrasound Med Biol* 2003; 29: 1273–1279.
5. Rossi A, Romanello I, Forzano I, Fachechi G, Marchesoni D: Evaluation of fetal cerebral blood flow perfusion using power Doppler ultrasound angiography (3D-PDA) in growth-restricted fetuses. *Facts Views Vis Ob-gyn* 2011; 3: 175–180.
6. Hata T, Tanaka H, Noguchi J: Transvaginal 3-d power Doppler ultrasound evaluation of the fetal brain at 10–13 weeks' gestation. *Ultrasound Med Biol* 2012; 38: 396–401.
7. Hsu JC, Wu YC, Wang PH, Wang HI, Juang CM, Chen YJ *et al.*: Quantitative analysis of normal fetal brain volume and flow by three-dimensional power Doppler ultrasound. *J Chin Med Assoc* 2013; 76: 504–509.
8. Conturso R, Contro E, Bellussi F, Youssef A, Pacella G, Martelli F *et al.*: Demonstration of the pericallosal artery at 11–13 weeks of gestation using 3D ultrasound. *Fetal Diagn Ther* 2015; 37: 305–309.
9. Dall'Asta A, Grisolia G, Volpe N, Schera GBL, Sorrentino F, Frusca T *et al.*: Prenatal visualisation of the torcular herophili by means of a Doppler technology highly sensitive for low-velocity flow in the expert assessment of the posterior fossa: a prospective study. *BJOG* 2021; 128: 347–352.